Precision Pain Management

A Personalized Approach to Stem Cell Therapy.

Dr. Drew DeMann



Dr. Drew DeMann

Director
Manhattan Medicine

- Primary Care Sports Medicine
- Orthopedic Spine Surgery
- Physical Medicine & Rehabilitation
- Orthopedic Pain Management
- Anesthesiology
- Physical Therapy
- Chiropractic

- **Primary Care Sports Medicine**
- **Orthopedic Pain Management**
- **Regenerative Medicine**
- **Ultrasound Guided Injections**

Brandeis

Bachelors
Biologic Sciences

NEW YORK UNIVERSITY

Masters Science
Orthopedic Biomechanics

NEW YORK CHIROPRACTIC COLLEGE

Doctor Of Chiropractic

SAMFORD UNIVERSITY

Orthopedic Pain Management
Family Nurse Practice

HARVARD MEDICAL SCHOOL

Global Clinical Research Scholar

“Pain management, pain medicine, pain control or algiatry, is a branch of medicine employing an interdisciplinary approach for **easing the suffering and improving the quality of life** of those living with pain.”

–

Hardy, Paul A. J. (1997). Chronic pain management: the essentials. U.K.: Greenwich Medical Media. ISBN 1-900151-85-5.

“**Precision pain management** involves the accurate identification of a patient’s pain source and the application of therapies that create lasting improvement.”

– Drew DeMann

How do we currently control / manage pain ?

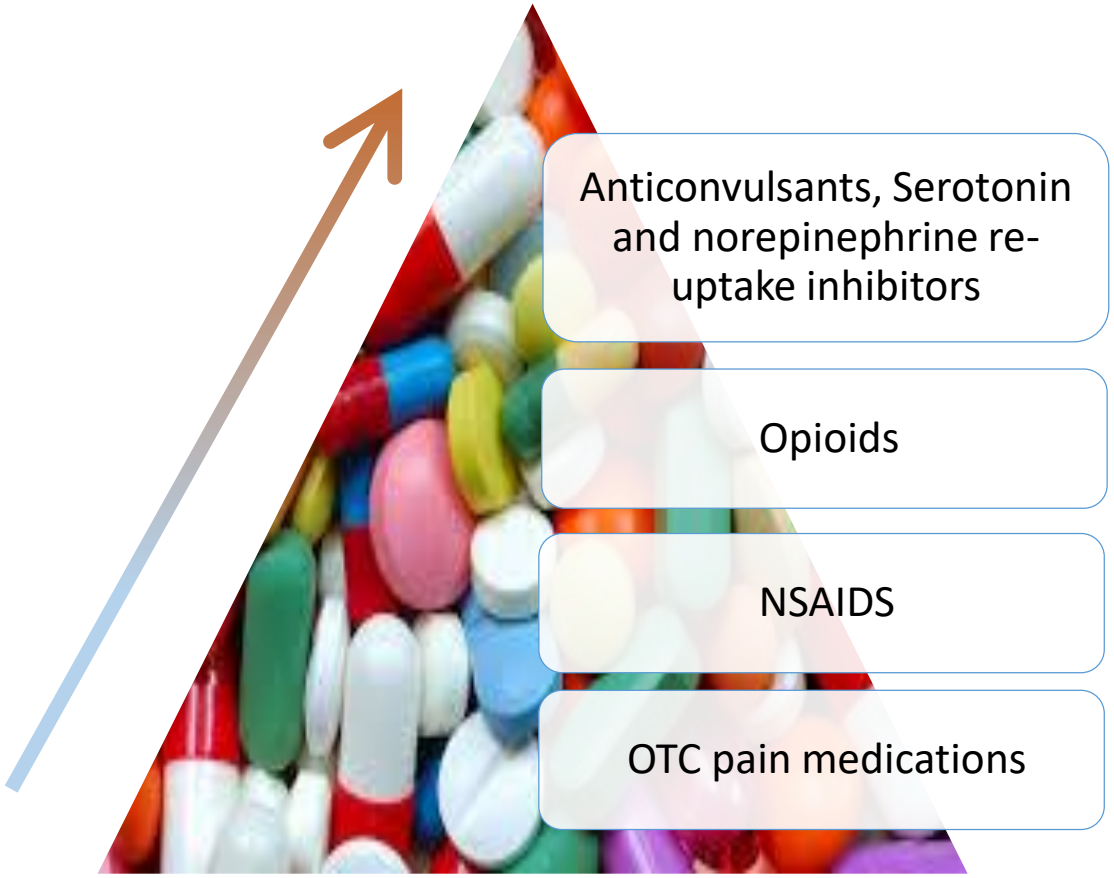

Medications

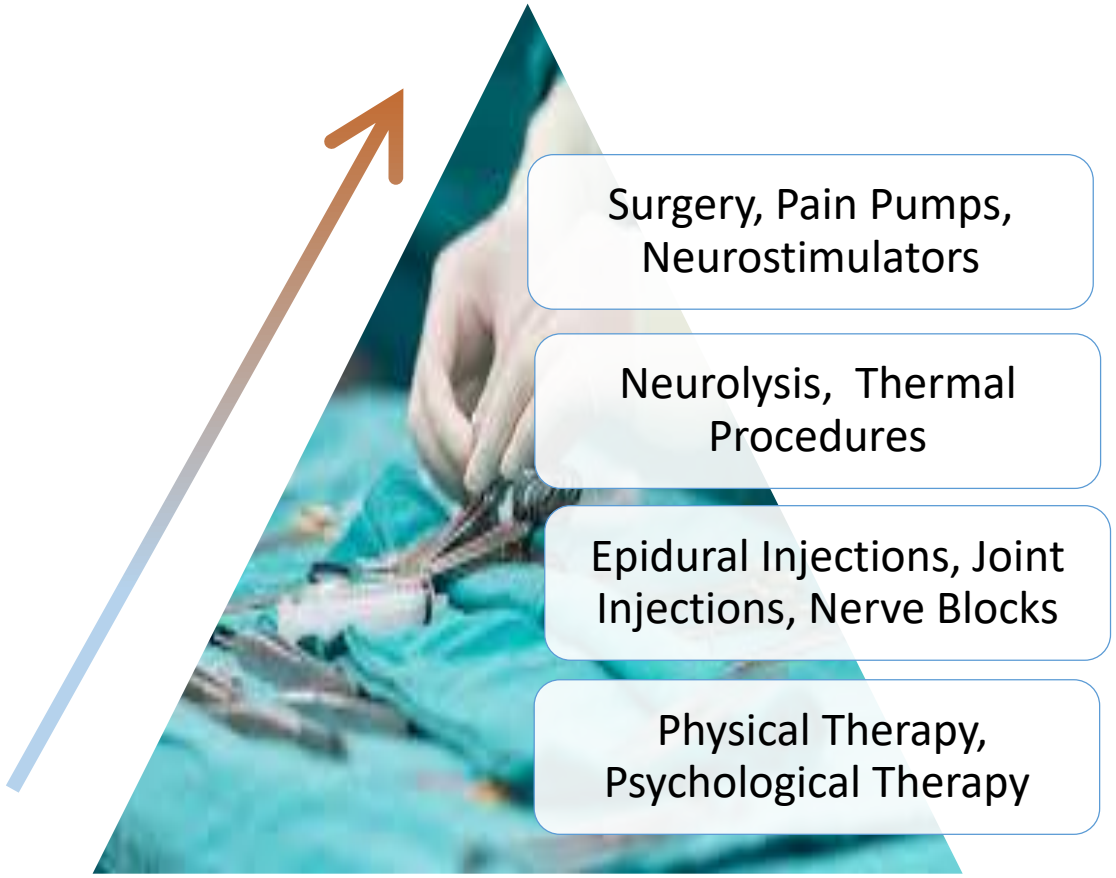

Procedures

What if we had method to identify the **source** of the pain and create **lasting** improvement… rather than just ”manage it”?

- Most chronic pain patients present with one or more physical structures such as muscle, joint, tendon, nerve or ligament that remain in a state of disrepair producing **persistent complex pain**.

- We know that many people who have chronic musculoskeletal or neurologic pain have, for one reason or another, **failed to fully heal**.

- What if we had a way to re-intiate **healing** or **regeneration** of a painful structure stopping the source of pain?

Regenerative Medicine

Regenerative medicine is a branch of medicine which is involved with “the process of replacing, engineering or regenerating human cells and tissues”.

> “Regenerative medicine is a game-changing area of medicine with the potential to fully heal damaged tissues and organs, offering solutions and hope for people who have conditions that today are beyond repair.”
>
> –
>
> Mayo Clinic 2017 http://www.mayo.edu/research/centers-programs/center-regenerative-medicine/patient-care/about-regenerative-medicine

Regenerative Medicine

- Regeneration involves delivering specific types of cells or cell products to diseased tissues, where they will ultimately restore tissue function.
- This can be done through **cell-based therapy** or by using cell products, such as growth factors.
- One example of cell-based therapies are the transplantation of **autologous stem cells** from either bone marrow or adipose tissue to area an of tissue injury.

Stem Cell Therapy

- **Stem cells** are a class of undifferentiated **cells** that are able to differentiate into specialized cell types.

- **Stem cells** come from two main sources:

  Embryos formed during the blastocyst phase of embryological development (**embryonic** stem cells)

  Adult tissue (**adult** stem cells).

Adult Stem Cells

Multipotent

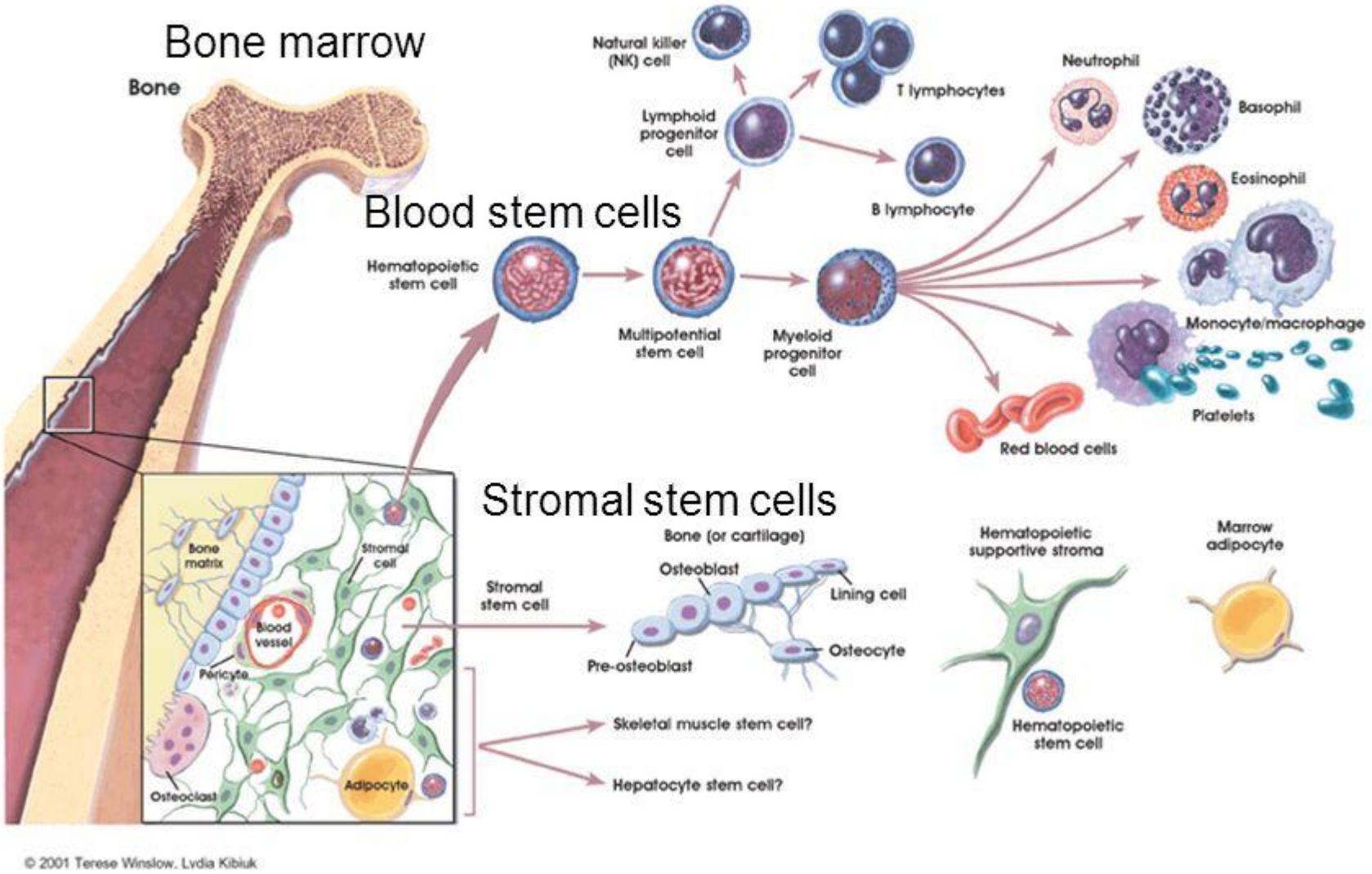

© 2001 Terese Winslow, Lydia Kibiuk

Mesenchymal Stem/Stromal Cells (MSC)

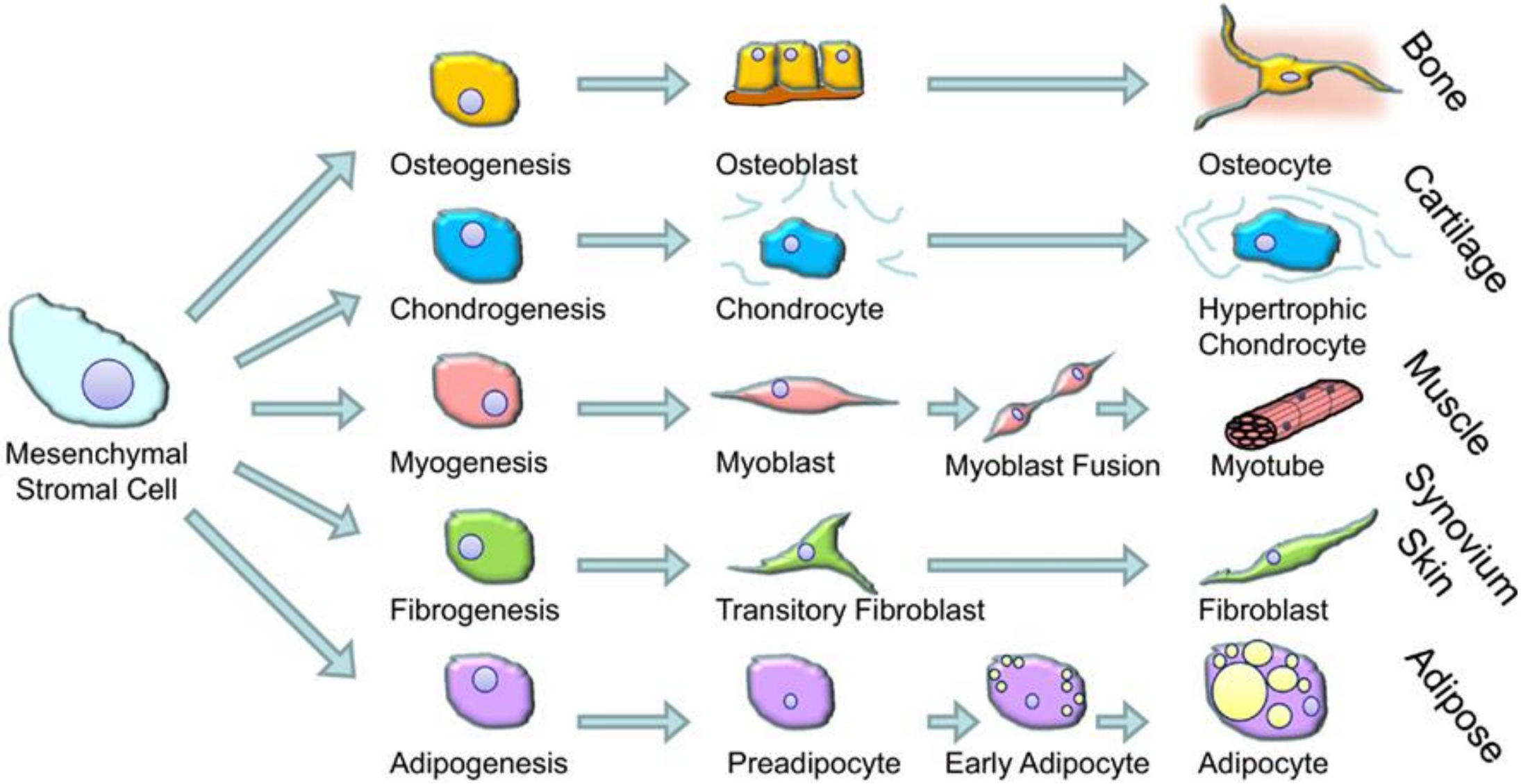

The MSC: An Injury Drugstore

MSCs are released from their perivascular location, become activated, and establish a regenerative microenvironment by secreting bioactive molecules and regulating the local immune response.

These trophic and immunomodulatory activities suggest that MSCs may serve as **site-regulated "drugstores" in vivo**.

Cell Stem Cell
Arnold Caplan, Diego Correa
Volume 9, Issue 1, p11-15, 8 July 2011

Mesenchymal Stem Cells…

could be called..

“Medicinal Signaling Cells”

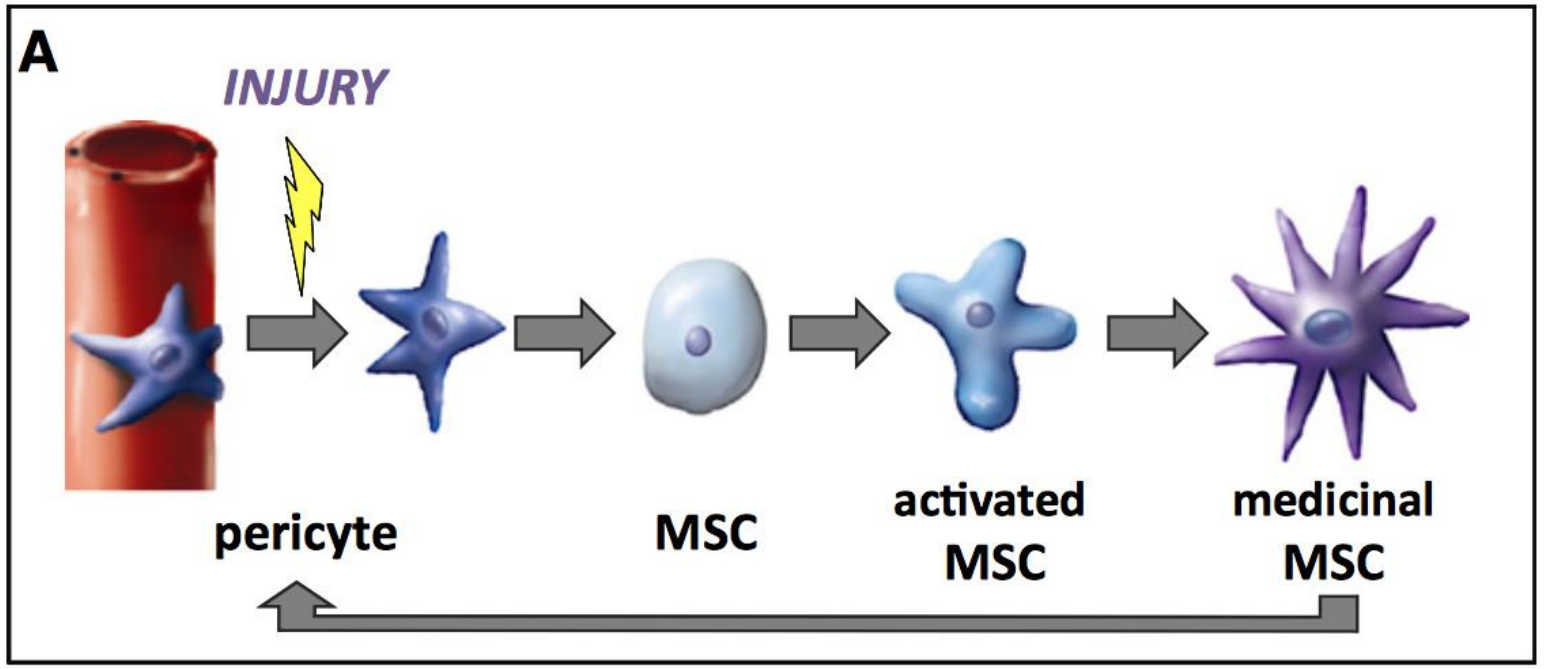

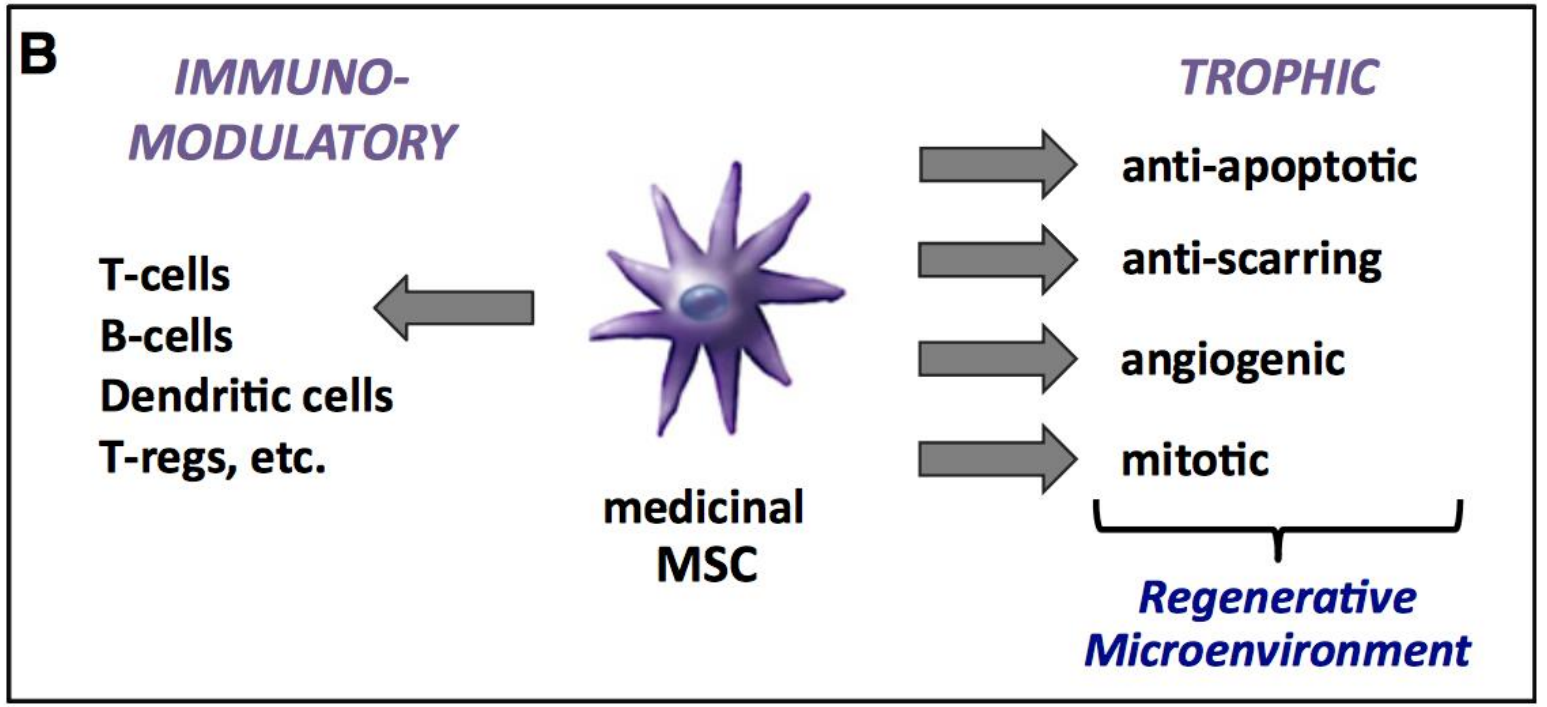

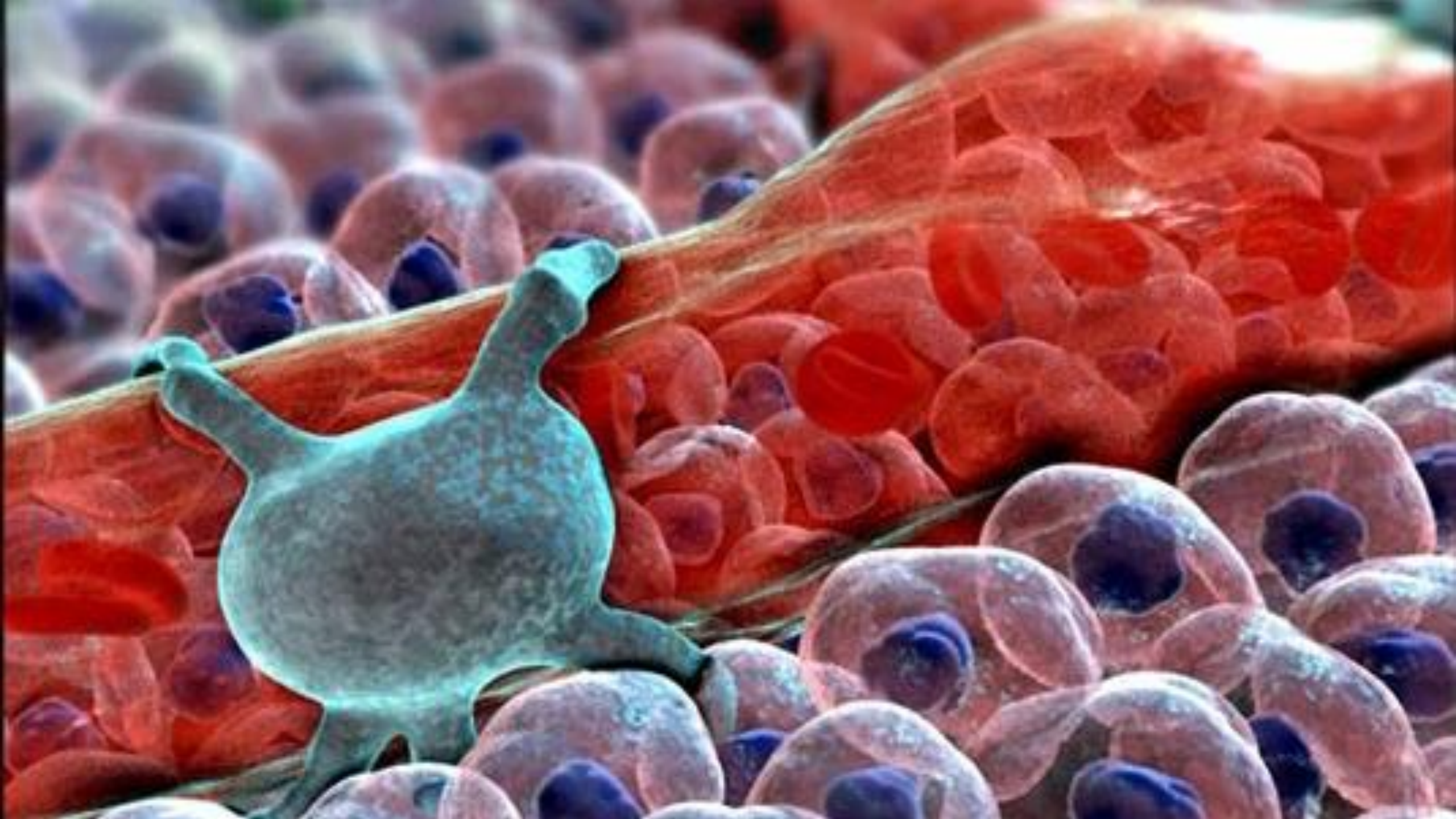

Stem Cell Treatment for MSK Related Pain

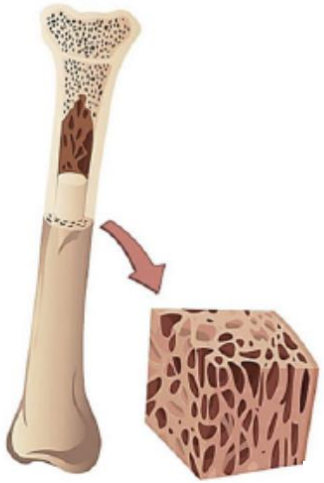

BONE MARROW

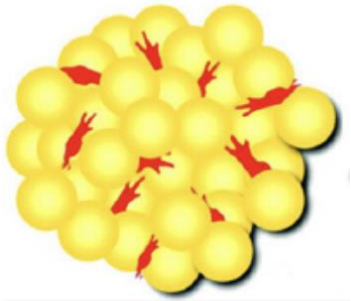

ADIPOSE TISSUE

- Stem cells are first **harvested** from either bone using **bone marrow** aspiration (BMA), or **from fat** through lipo-aspiration.
- In BMA yields both hematopoietic and mesenchymal stem cells (MSC). Fat derived stem cells are mostly MSCs.
- Stem cells are separated and concentrated through a process of filtration and centrifugation at the point of care.
- A concentrated stem cell preparation is applied to a specific target by injection, under real-time imaging guidance such ultrasound or fluoroscopy.



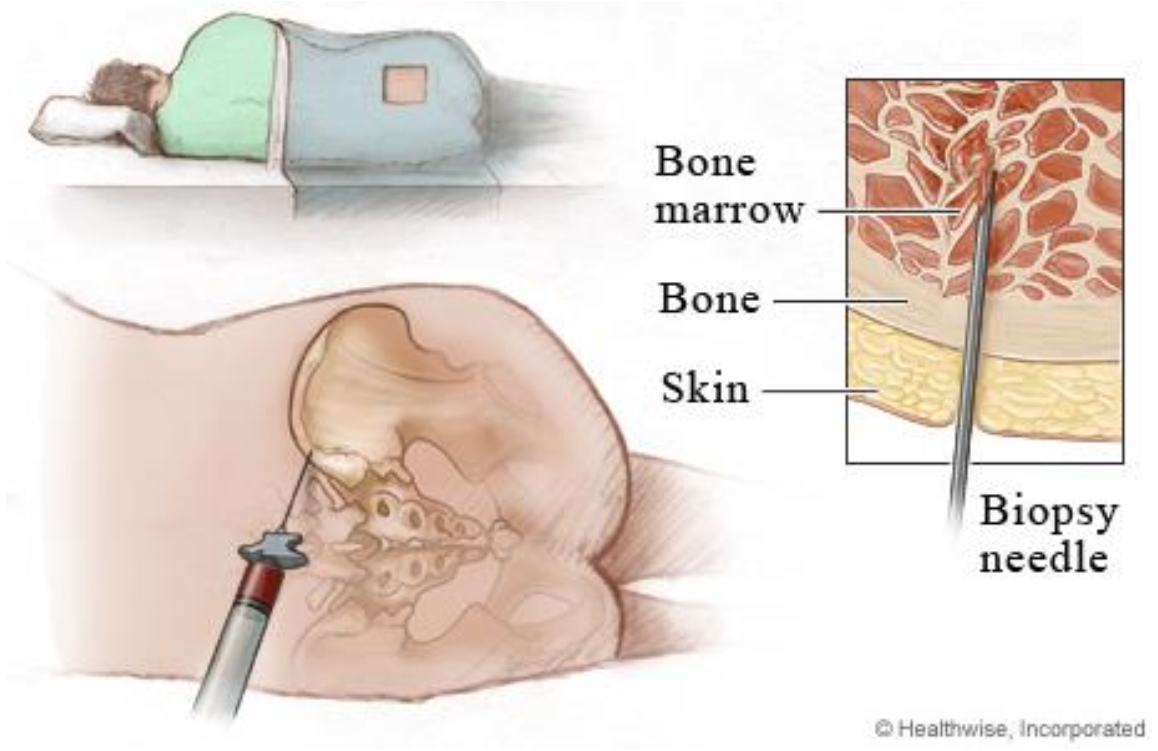

Bone Marrow Aspiration

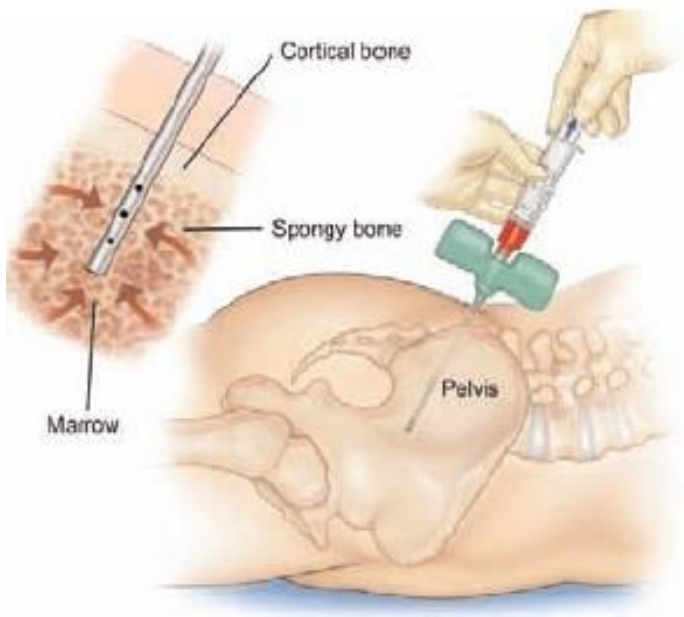
Cortical bone
Spongy bone
Pelvis
Marrow




HARVEST







Lipo-aspiration of Stem Cells



Lipoaspirant

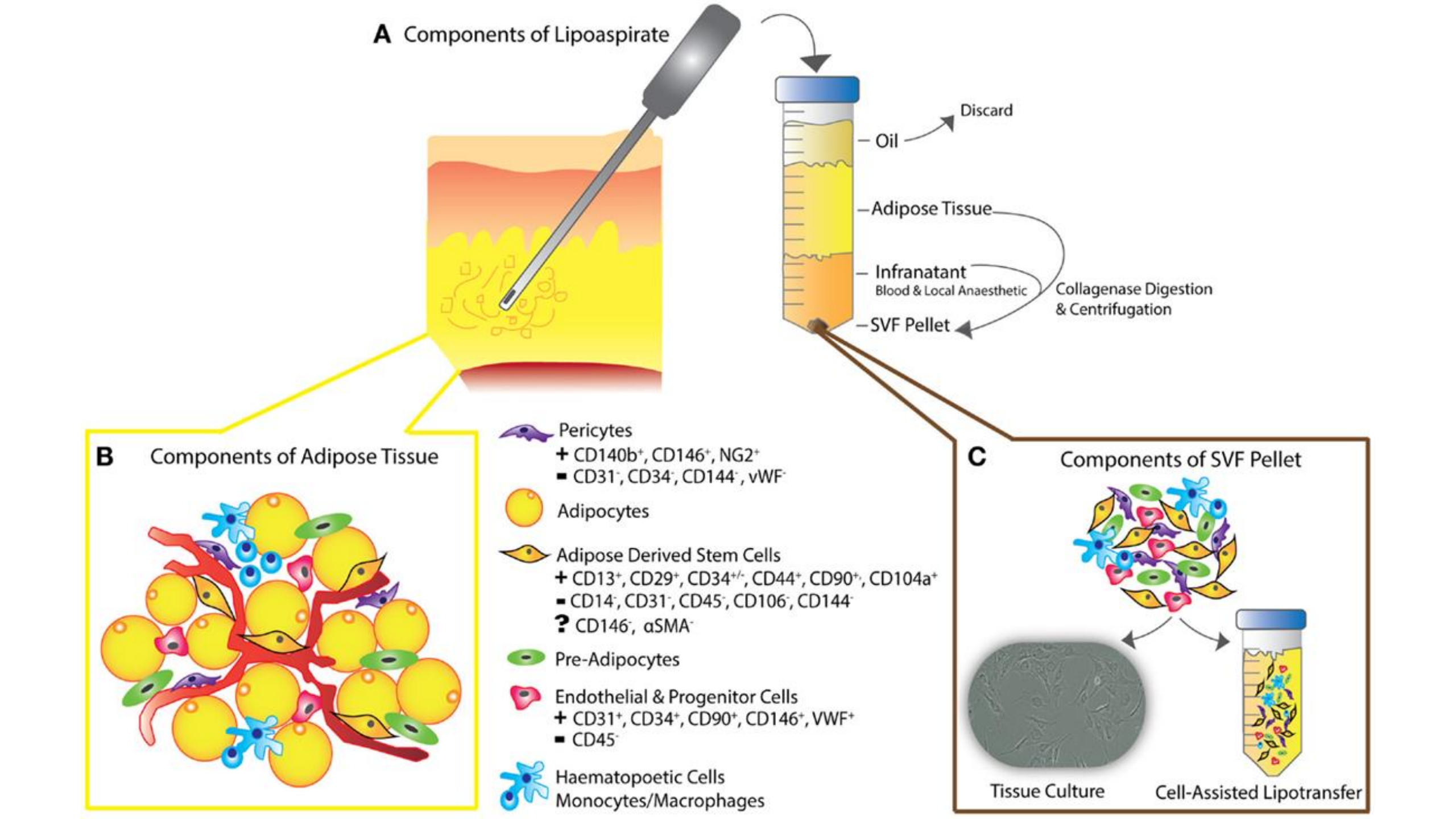
A Components of Lipoaspirate
Discard
Oil
Adipose Tissue
Infranatant
Blood & Local Anaesthetic
Collagenase Digestion
& Centrifugation
SVF Pellet
B Components of Adipose Tissue
Pericytes
+ CD140b+, CD146+, NG2+
- CD31-, CD34-, CD144-, vWF-
Adipocytes
Adipose Derived Stem Cells
+ CD13+, CD29+, CD34+/-, CD44+, CD90+, CD104a+
- CD14-, CD31-, CD45-, CD106-, CD144-
? CD146-, αSMA-
Pre-Adipocytes
Endothelial & Progenitor Cells
+ CD31+, CD34+, CD90+, CD146+, VWF+
- CD45-
Haematopoetic Cells
Monocytes/Macrophages
C Components of SVF Pellet
Tissue Culture
Cell-Assisted Lipotransfer



Final Stem Cell Preparation

Clinical Application of Stem Cells in MSK Pain



Before we can administer stem cells, we need to remember….

1. The location of the source of pain isn't always where it presents.
2. Imaging is an anatomical picture (MRI, XR), not functional representation of pain. It can hint as to where the source is but also can be misleading.
3. Most chronic MSK pain patients often have more than one source.

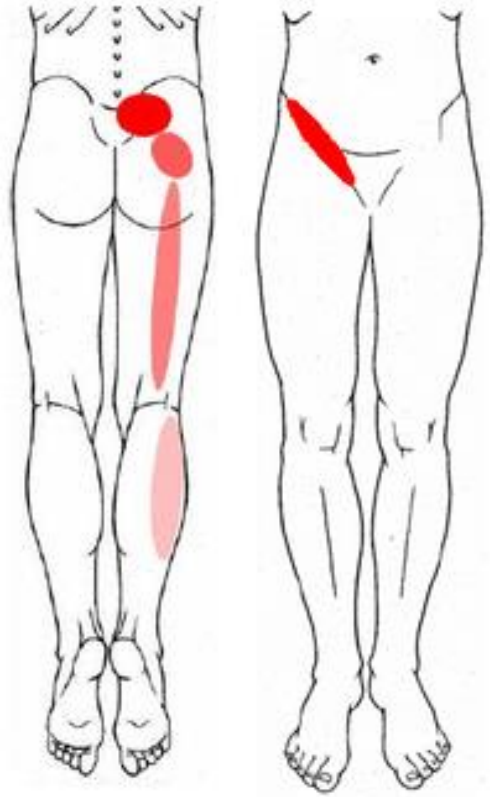

MRI REPORT

1. *Multilevel lumbar spondylosis w mod central canal stenosis*
2. *Facet Arthrosis at L2-3, L3-4, L4-5, L5-S1*
3. *Mild disc protrusion at L2-3,L3-4, L4-5*
4. *S/P L4-L5 laminectomy*
5. *Mild right S1 root compression*
6. *Mild right sacroiliac joint arthrosis*
7. *Mod to severe R hip OA*

HX: DJD R hip, LBP with lumbar scoliosis post laminectomy syndrome, lumbar spinal stenosis, facet and sacroiliac joint syndrome, and R hip pain w DJD.

SUBJECTIVE: 77-yo WF R LP. PHx L4-5 laminectomy for spinal stenosis, LBP lumbar scoliosis, post laminectomy syndrome, lumbar spinal stenosis, and R L4 radiculopathy. R L4-L5 TF ESI x 2. XR R hip degenerative with progression to prior studies. R intra-articular hip inj. marginal relief. Considering hip replacement. C/O of significant pain R hip, incr with weightbearing, movement. Ultracet or, up to 4qd. Cane to ambulate.

REFERRAL IMPRESSION:

1. DDD of the R hip, symptomatic.
2. LBP syndrome, spinal stenosis, clinically R L4 radiculopathy.
3. LBP w scoliosis post laminectomy syndrome, stable.
4. Facet and R SIJ syndrome.
5. R hip pain with moderate OA.
6. Chronic pain syndrome.

Confirmation of Pain Source

- Most chronic pain patients have failed multiple prior forms of care or intervention.
- The diagnosis is NEVER certain in chronic pain patients.
- Imaging can be misleading and often does not tell the whole story.
- All patients should under go a process of “diagnostic confirmation” before therapeutic injection (of stem cells).
- This involves demonstrating that pain can be **temporarily blocked or altered by applying a local anesthetic to suspected source**.

Verify Pain Source Before Treatment

- Diagnostic Injections can be applied to almost any suspected pain producing structure to verify contribution
  - Joint
  - Ligament
  - Tendon
  - Nerve
  - Muscle

- Once the pain producing target is confirmed by diagnostic injection the patient will be scheduled for the stem cell transplant and treatment.

Stem Cell Treatment

- Stem cell treatments should be precisely applied.
- Prior to injected, the patient undergoes a series of diagnostic visits to confirm the source of their pain.
- This includes in most cases a series 2-3 “diagnostic injections” or “blocks”.
- Each block must produce at least a 50% reduction in pain for the patient to progress to treatment unless there is overwhelming imaging evidence.

Diagnostic Injection

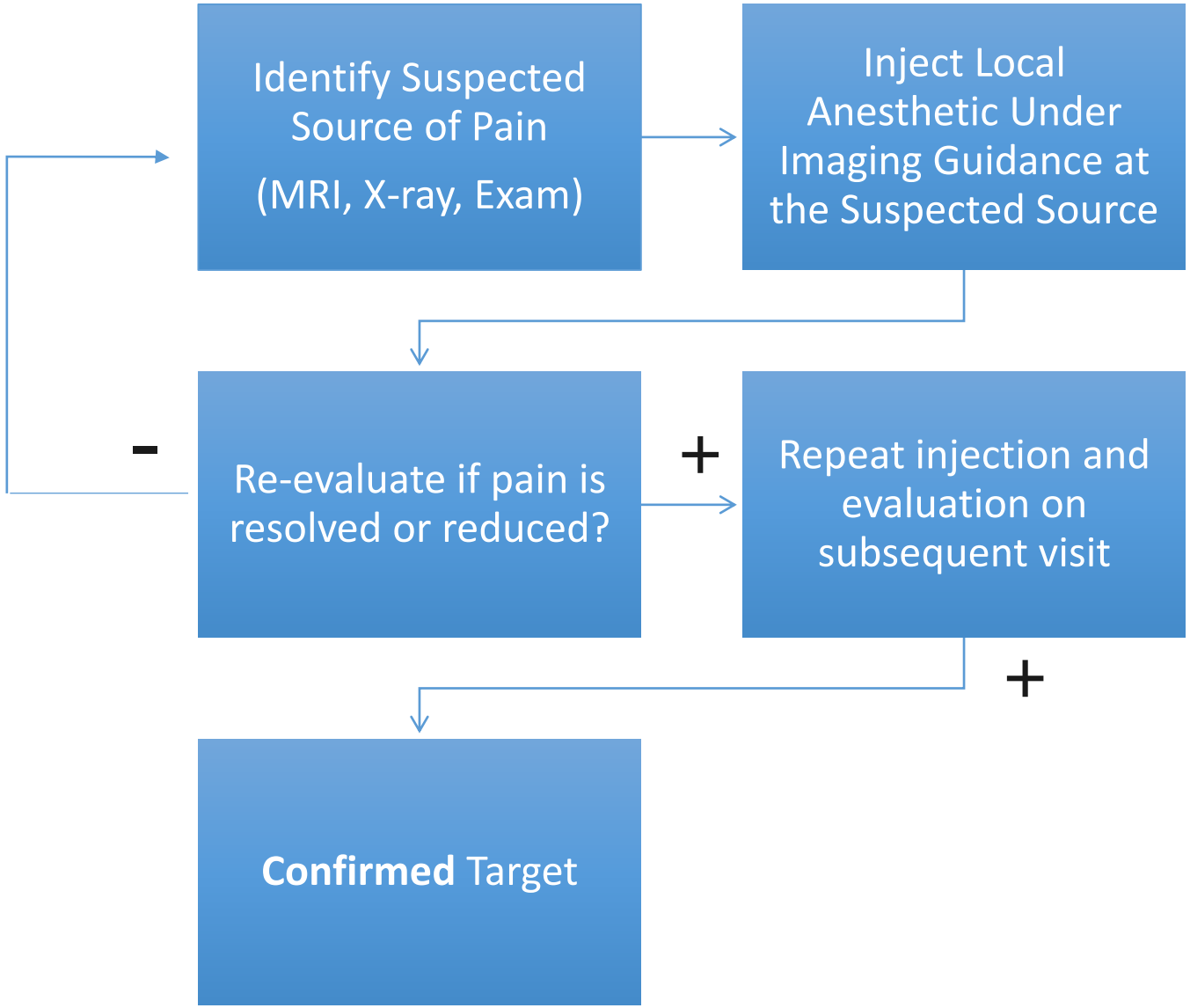

Fluoroscopic Guided Injection / Diagnostic Block

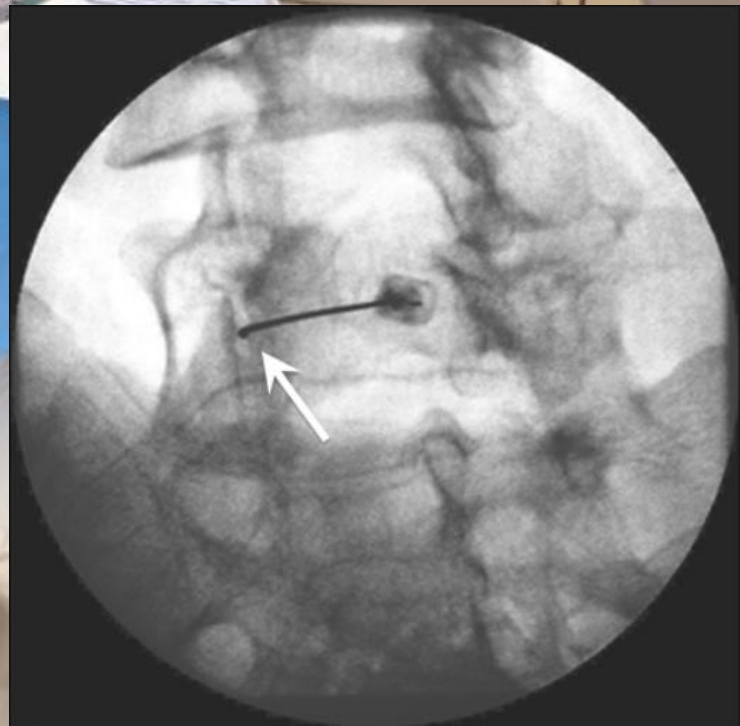

Stem Cells Treatments

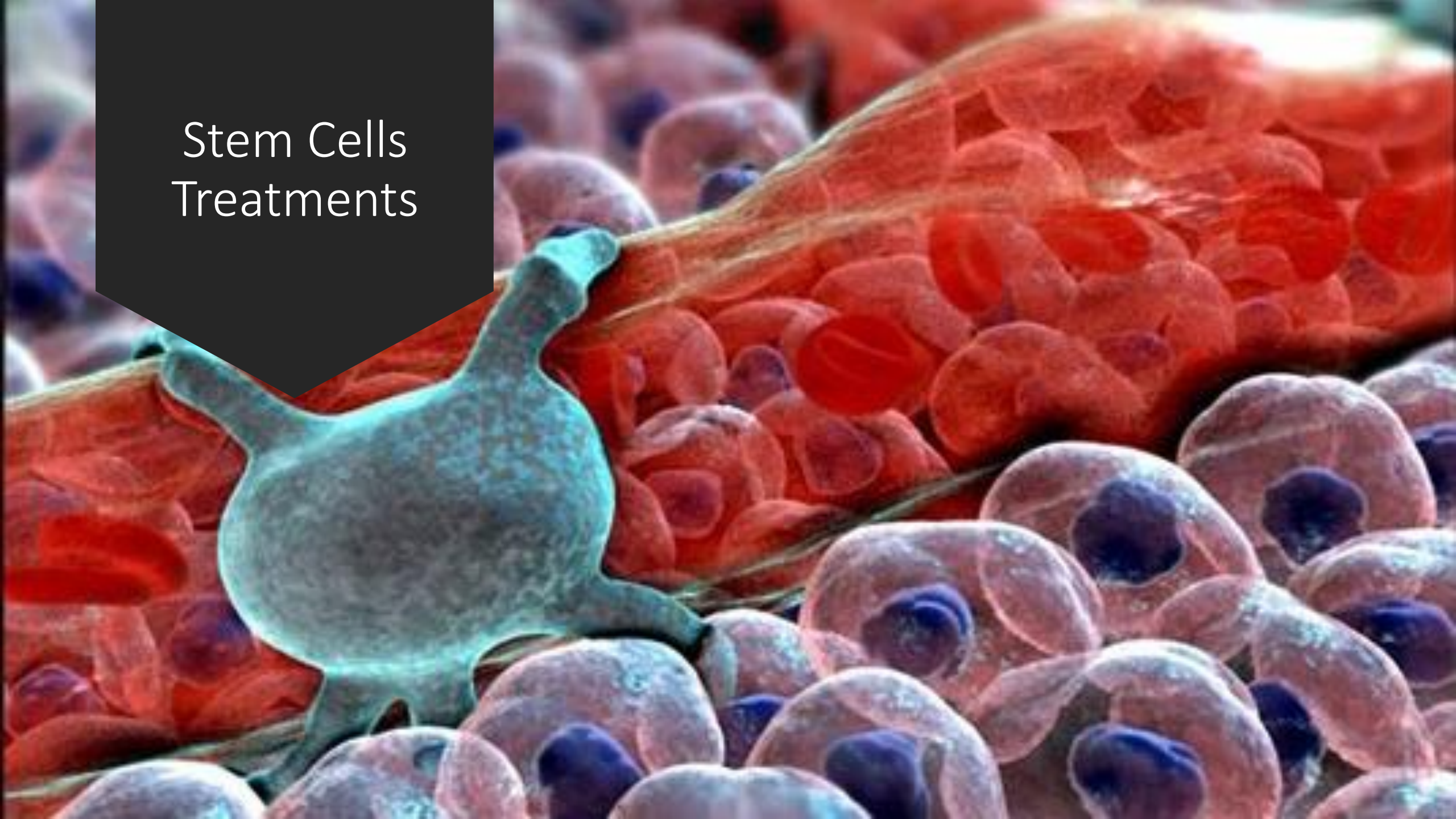

Stem Cell Treatment of the Spine

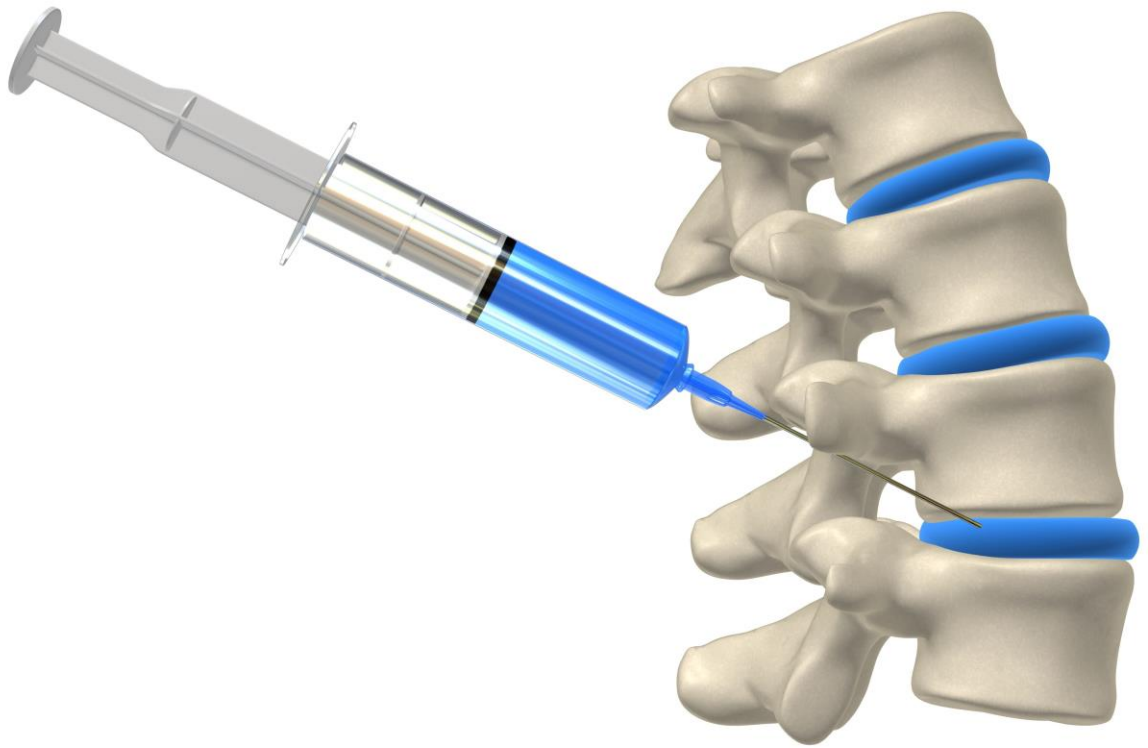

Studies

Intervertebral disc repair by autologous mesenchymal bone marrow cells: a pilot study.

Ten patients with persistent discogenic LBP, DDD (>50% disc height loss), and an intact outer annulus (per discography) underwent a single injection after failing 6 months of conservative treatment. The authors reported statistically significant improvements in both pain and disability after 3 months, with results persisting at one year. Although there was no recovery of disc height on MRI, water content of the discs significantly improved at one year.

Orozco L, Soler R, Morera C, Alberca M, Sánchez A, García-Sancho J Transplantation. 2011 Oct 15; 92(7):822-8.

Studies

Percutaneous injection of autologous bone marrow concentrate cells significantly reduces lumbar discogenic pain through 12 months.

Twenty-six patients with discogenic LBP (DDD-Pfirrmann grades IV–VII) received percutaneously injected BMAC (same-day procedure). In 8 patients, provocative discography was used to confirm discogenic etiology. Authors found a reduction in ODI and VAS scores from 56.5 and 79.3 at baseline to 22.8 and 29.2 at 3 months, which continued throughout 12 months. Additionally, eight of twenty patients improved by one modified Pfirrmann grade (on MRI) at one year. Interestingly, authors found that patients receiving greater than 2,000 CFU/mL of MSCs experienced significantly faster and greater reductions in VAS and ODI scores.

Pettine KA, Murphy MB, Suzuki RK, Sand TT
Stem Cells. 2015 Jan; 33(1):146-56.

Studies

Percutaneous injection of autologous bone marrow concentrate cells significantly reduces lumbar discogenic pain through 12 months.

A prospective, multicenter, double-blinded RCT performed to evaluate safety and preliminary efficacy of allogeneic MSCs combined with an HA carrier in 100 patients with clinically determined single level disc pain and degeneration (Pfirrmann III–VI). Patients were randomized to receive a single injection of proprietary allogeneic low or high-dose MSCs + HA, HA-alone, or saline (control) and are followed for a 2-year period. After 1-year, 69% of the low-dose MSC and 62% of the high-dose MSC groups have showed greater than 50% reduction in VAS scores compared to 35% and 31% in HA-alone and saline groups. A mean reduction in ODI of 43% (high-dose MPC), 35% (low-dose MPC), 30% (HA-only), and 28% (saline) has been reported. After 48 months the lose-dose MPC group achieved minimal or no residual pain (VAS < or = 2) months compared to 38% of the saline-treated group.

Mesoblast Reports Positive 24 Month Results in Phase 2 Trial for Chronic Low Back Pain and Initiation of the Phase 3 Program at JP Morgan Healthcare Conference, January 2015, www.mesoblast.com.

Results

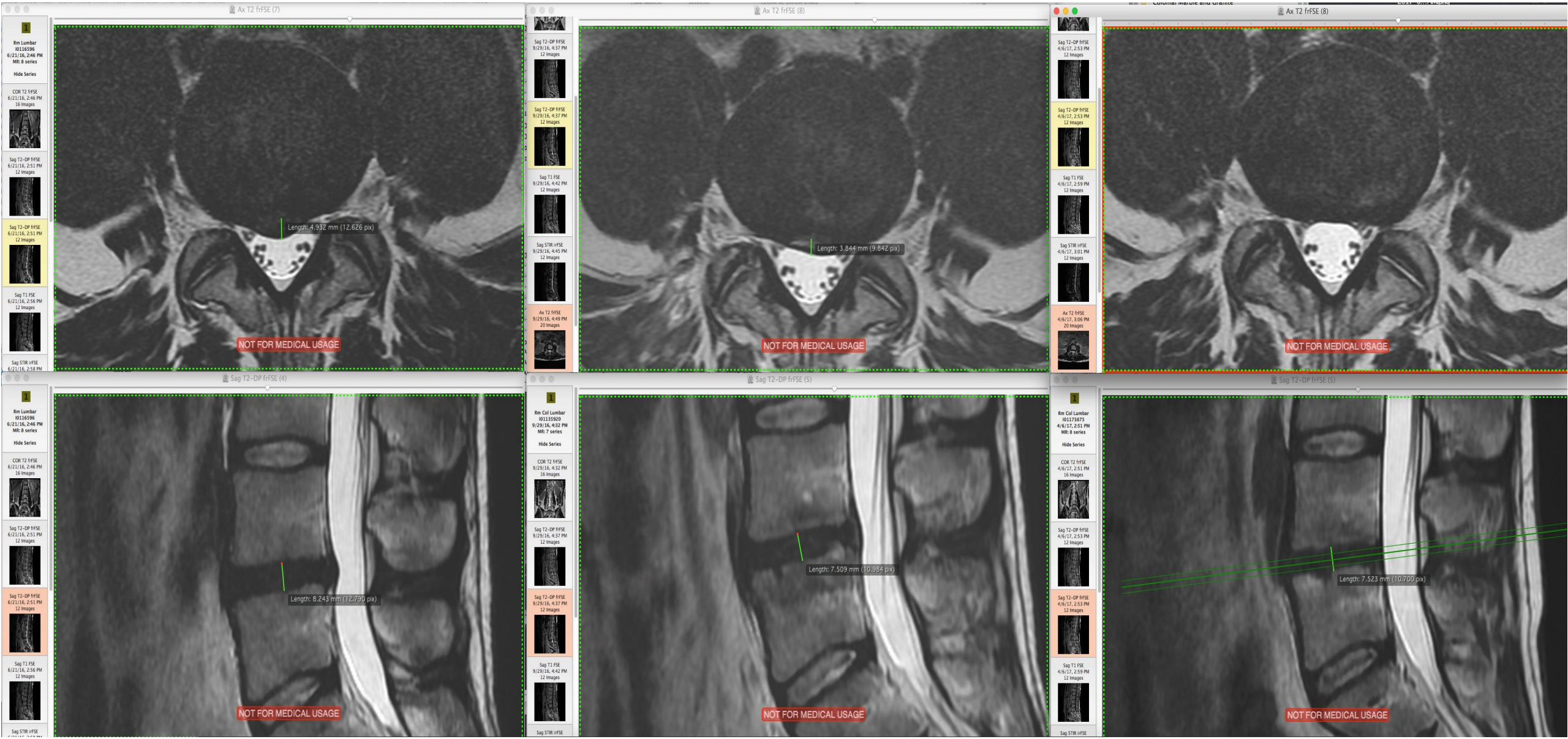
Ax T2 frFSE (7)
Length: 4.932 mm (12.626 pix)
NOT FOR MEDICAL USAGE
Ax T2 frFSE (8)
Length: 3.844 mm (9.842 pix)
NOT FOR MEDICAL USAGE
Ax T2 frFSE (8)
NOT FOR MEDICAL USAGE
Sag T2-DP frFSE (4)
Length: 8.243 mm (12.790 pix)
NOT FOR MEDICAL USAGE
Sag T2-DP frFSE (5)
Length: 7.509 mm (10.984 pix)
NOT FOR MEDICAL USAGE
Sag T2-DP frFSE (5)
Length: 7.523 mm (10.700 pix)
NOT FOR MEDICAL USAGE

Examples of where MSCs being currently used in MSK medicine?

- Tendons
  - Rotator Cuff Injuries / Incomplete Tendon Disruption or Defects
  - Tennis Elbow / Common Extensor Tendon Injuries / Defects
  - Golfers Elbow / Common Flexor Tendon Injuries
- Joints
  - Knee OA
  - Hip OA
- Ligaments
  - Knee: MCL / LCL / ACL
  - Ankle Instability: ATFL / CFL
- Spine
  - Disc
  - Facet

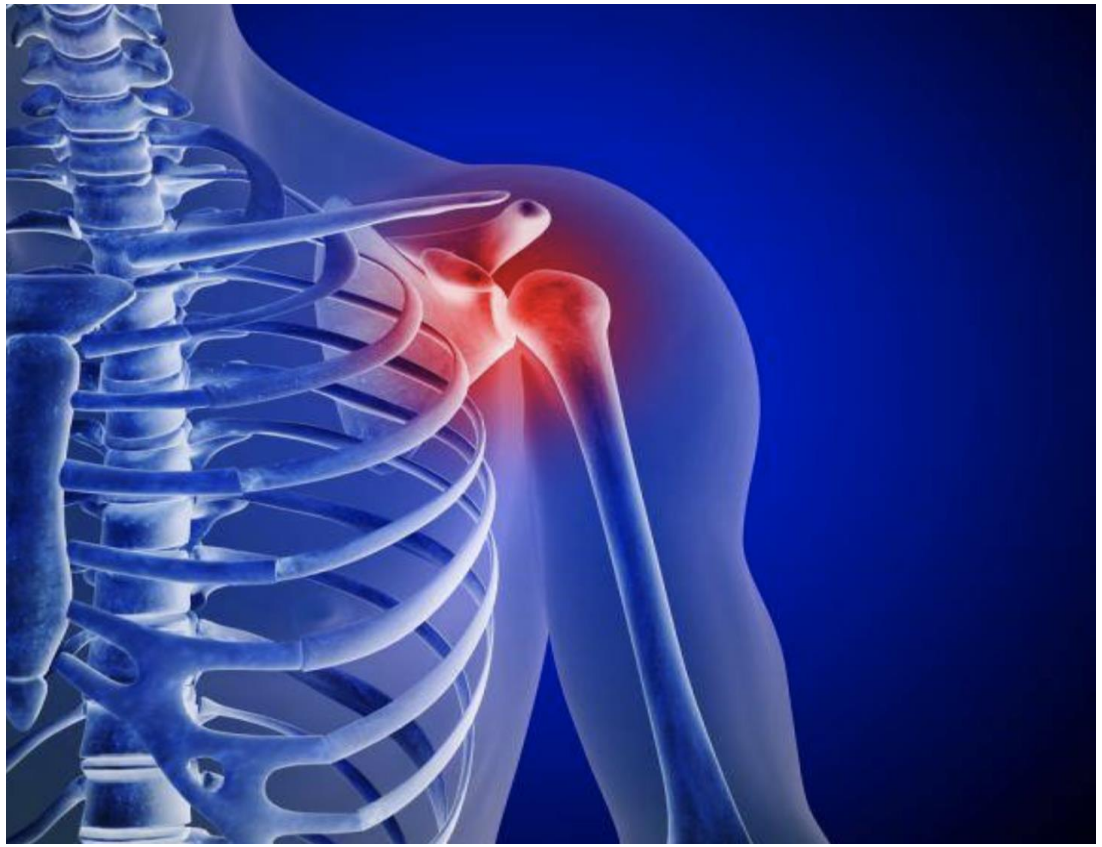

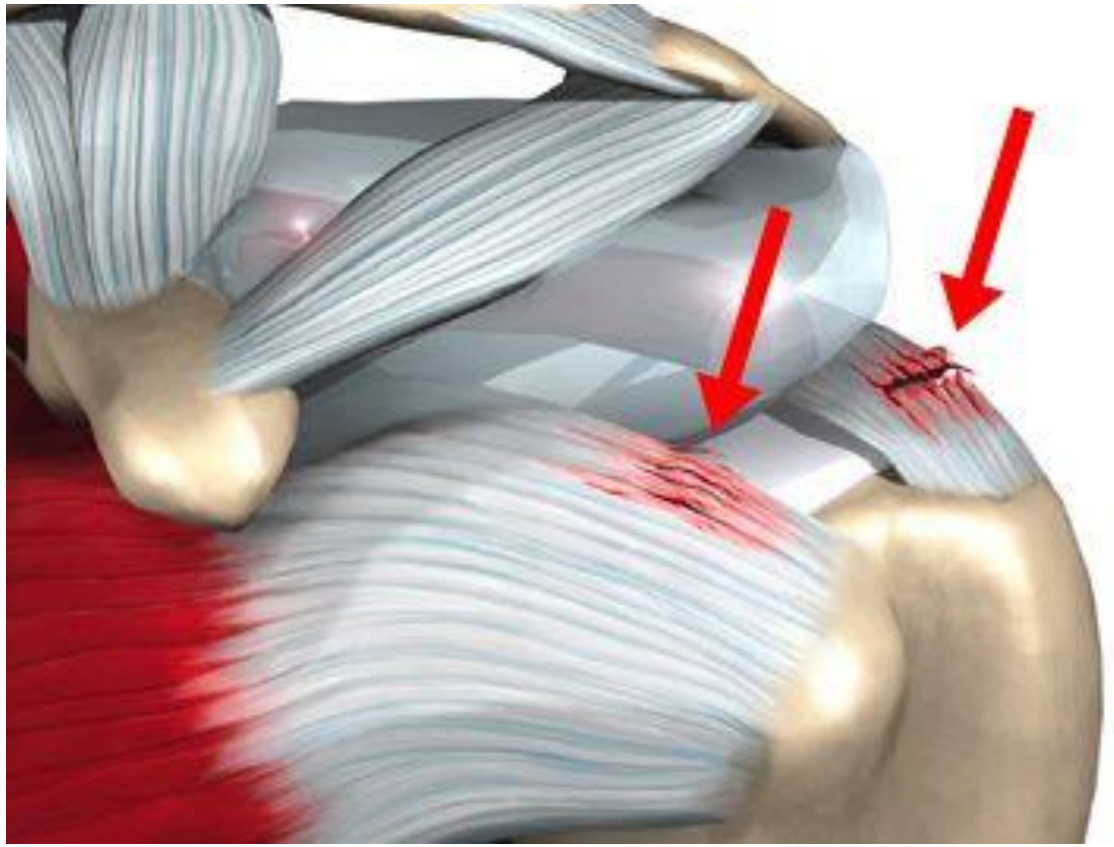

Stem Cell Treatment of Shoulder

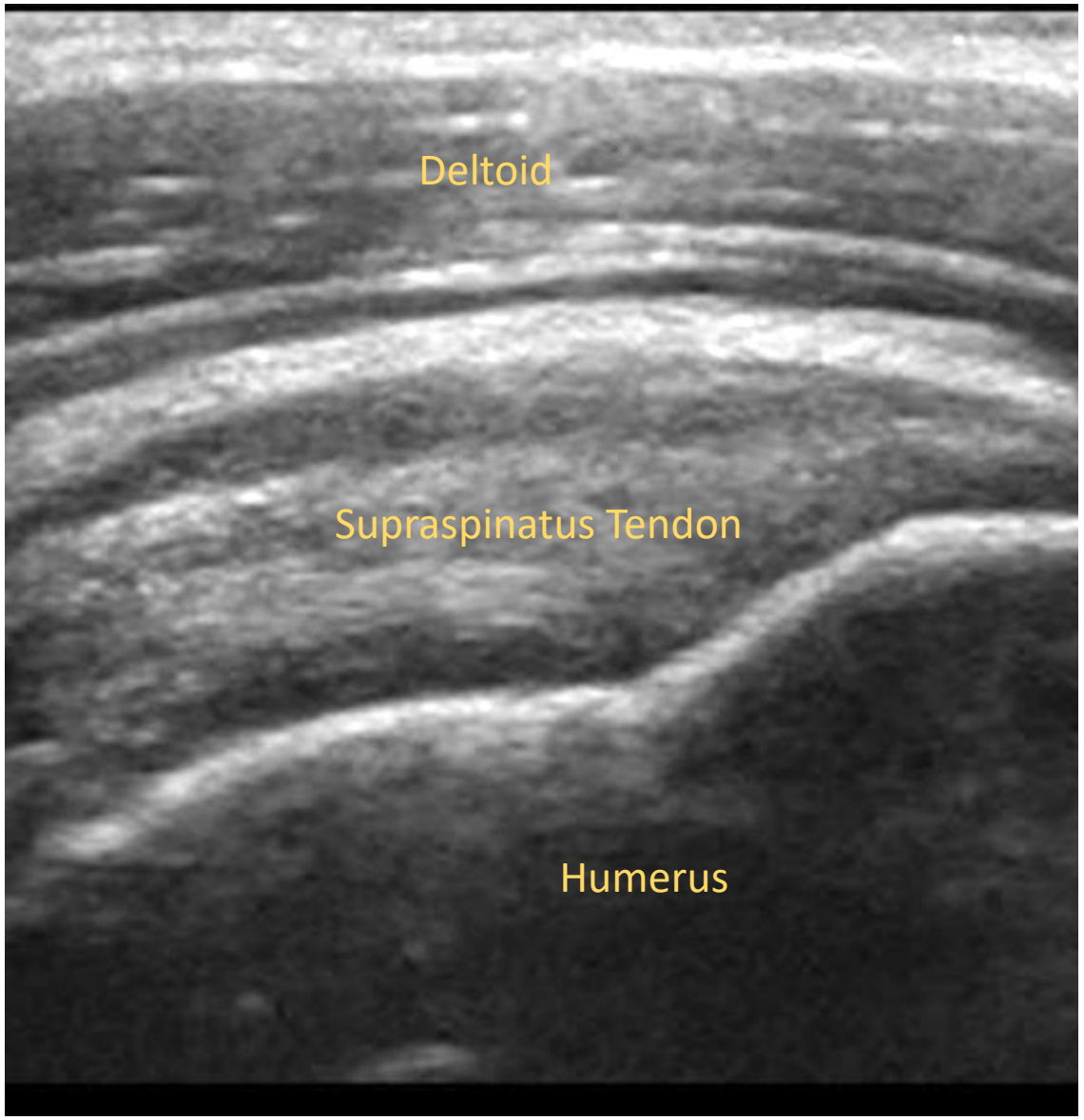
Deltoid
Supraspinatus Tendon
Humerus

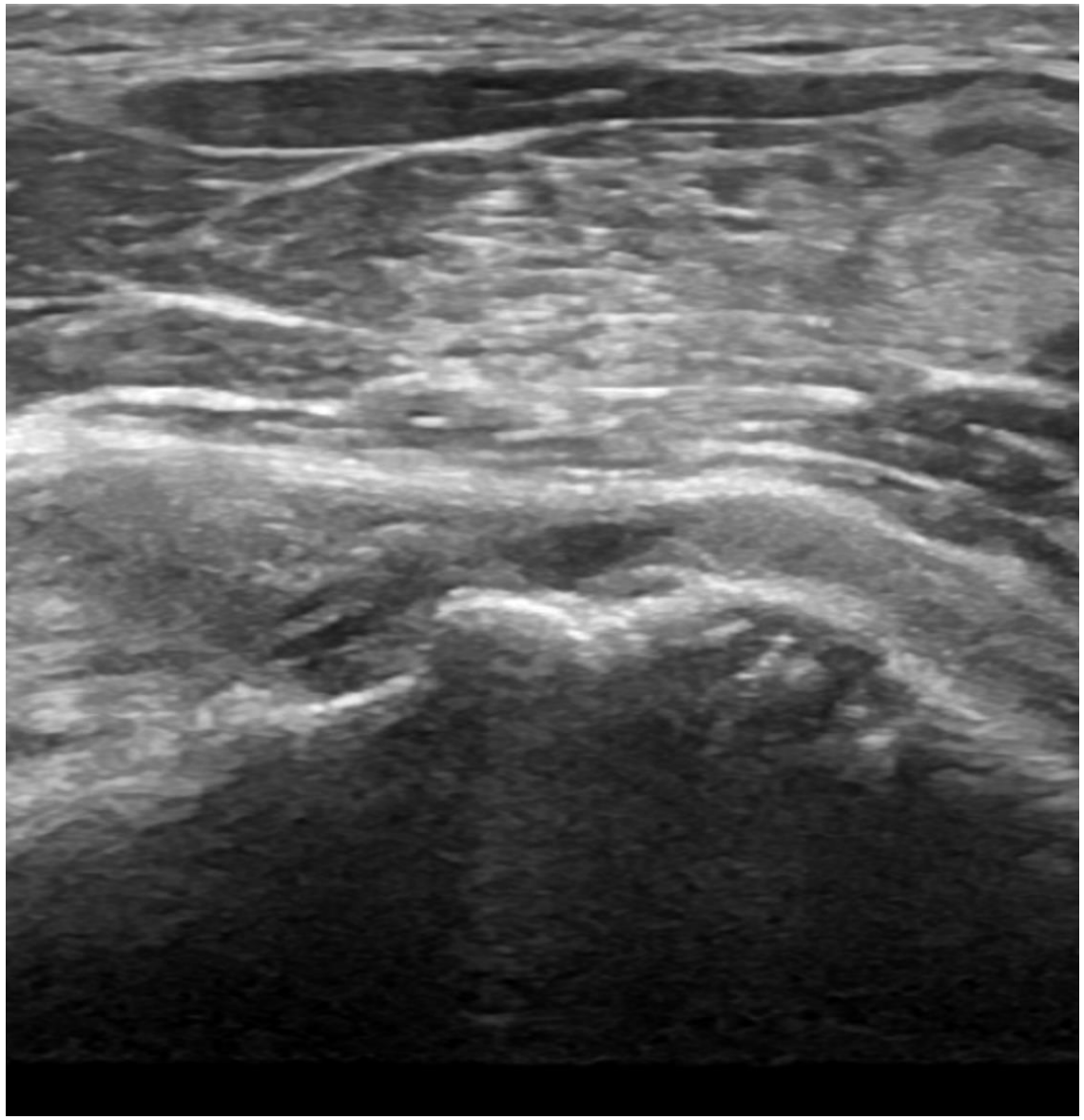

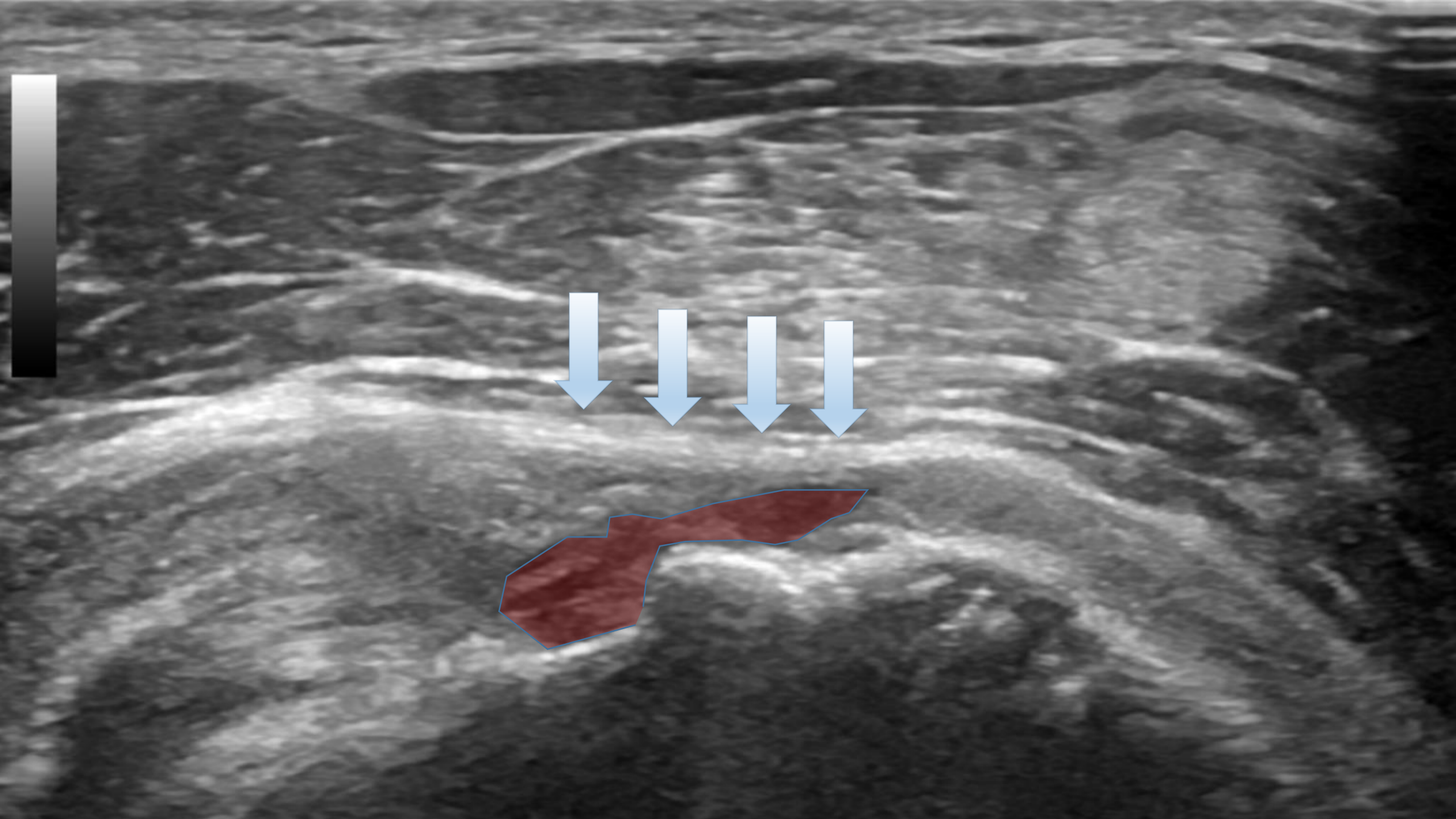

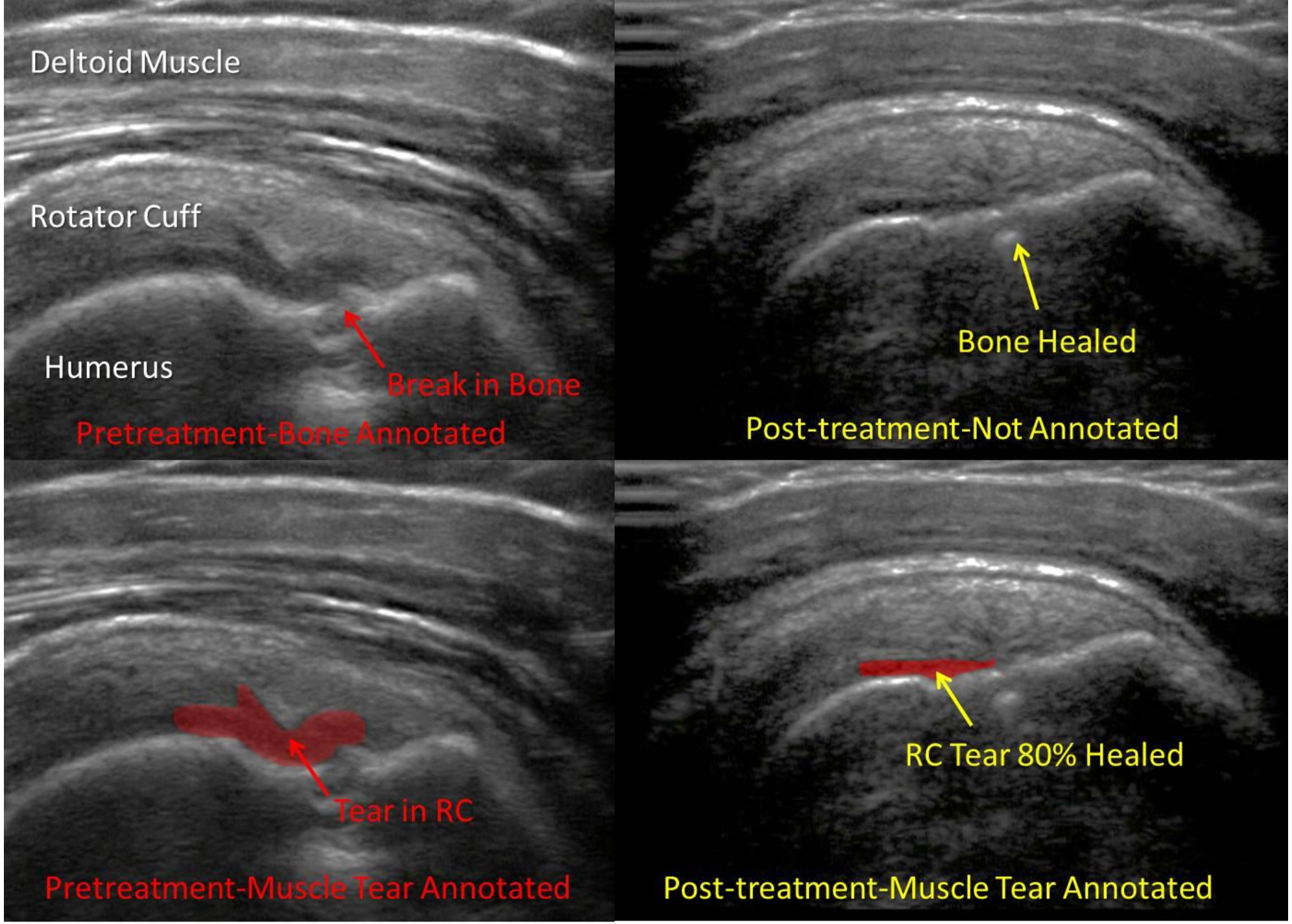
Deltoid Muscle
Rotator Cuff
Humerus
Break in Bone
Pretreatment-Bone Annotated
Bone Healed
Post-treatment-Not Annotated
Tear in RC
Pretreatment-Muscle Tear Annotated
RC Tear 80% Healed
Post-treatment-Muscle Tear Annotated

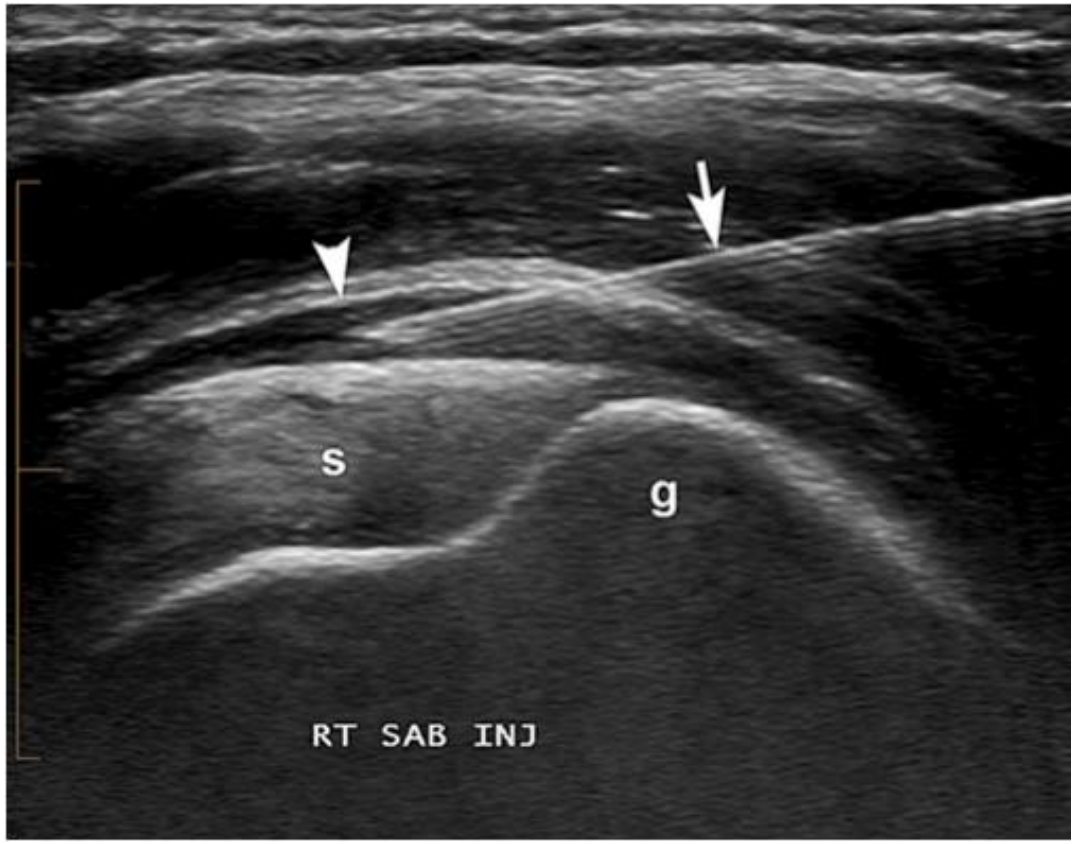

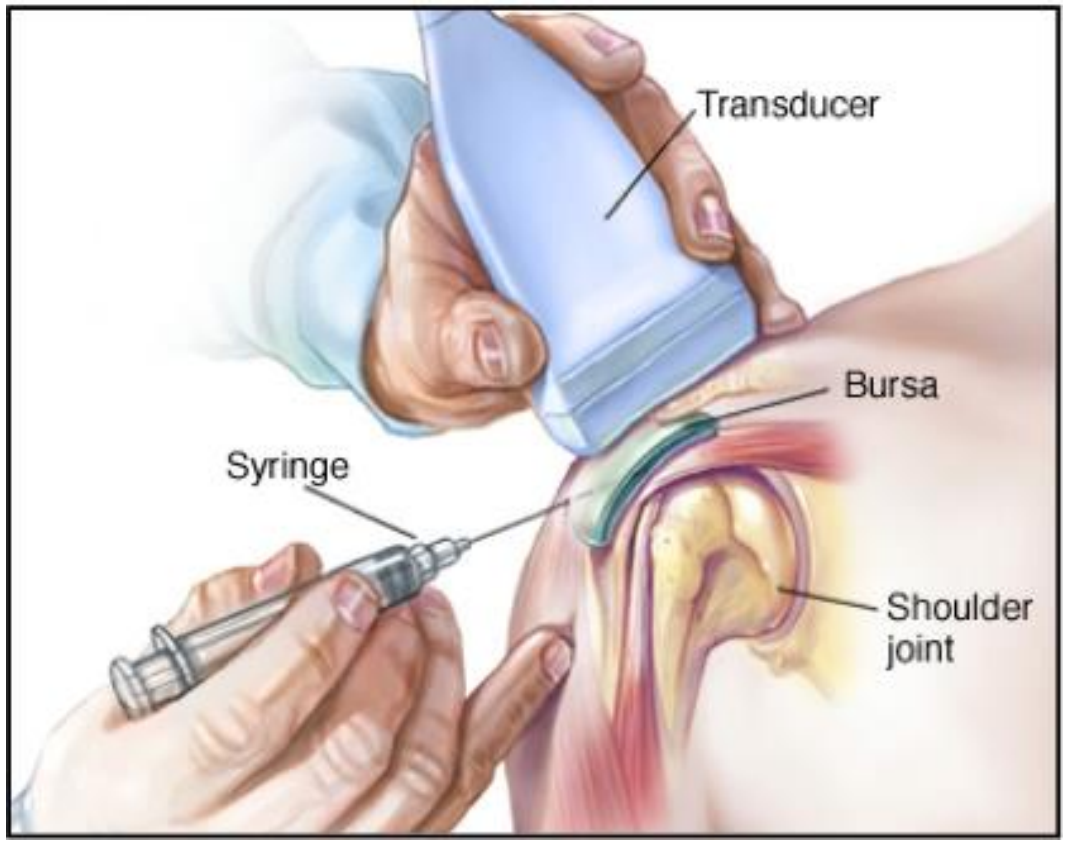

Ultrasound Guided Rotator Cuff / Bursa Injection

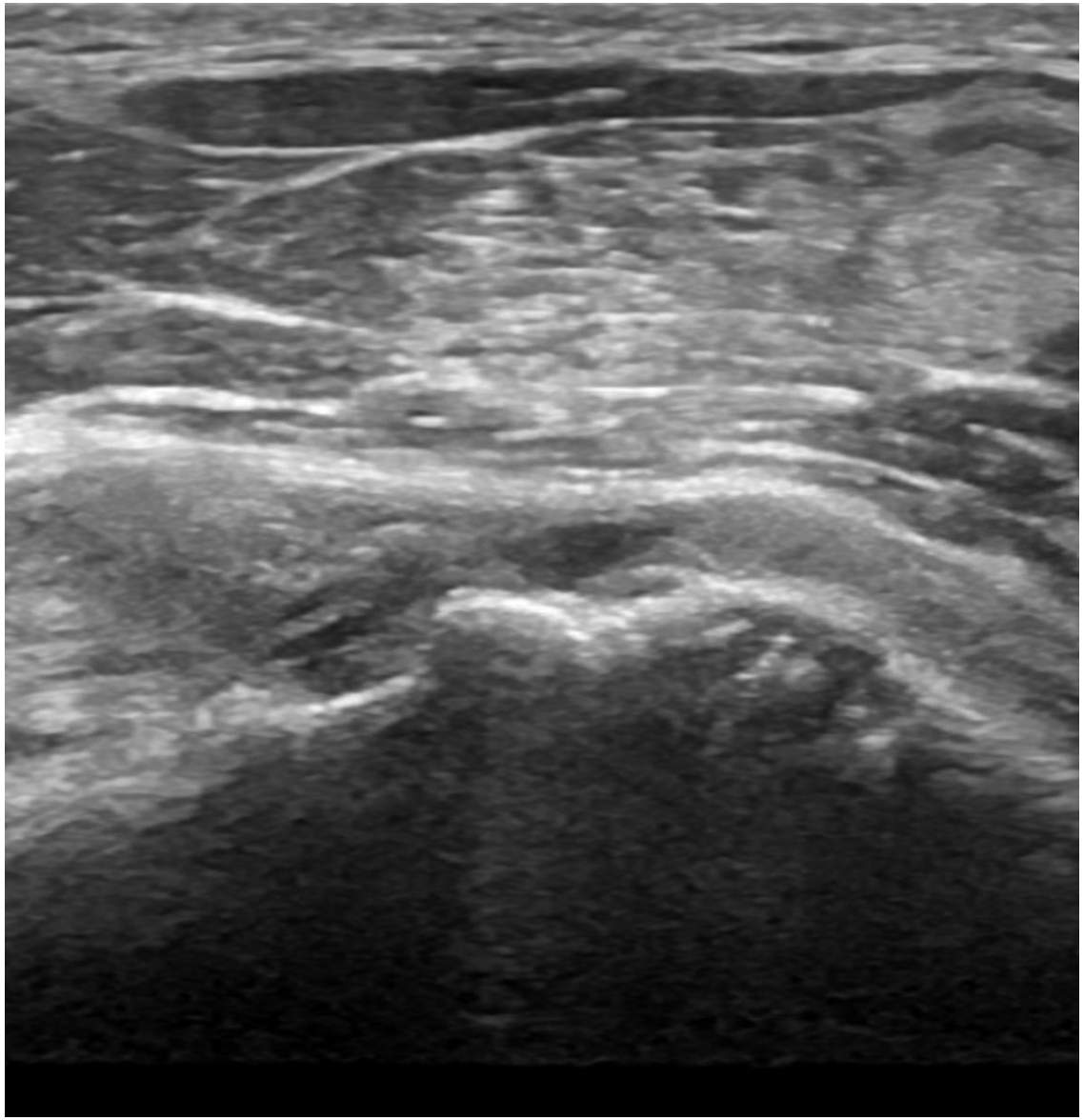

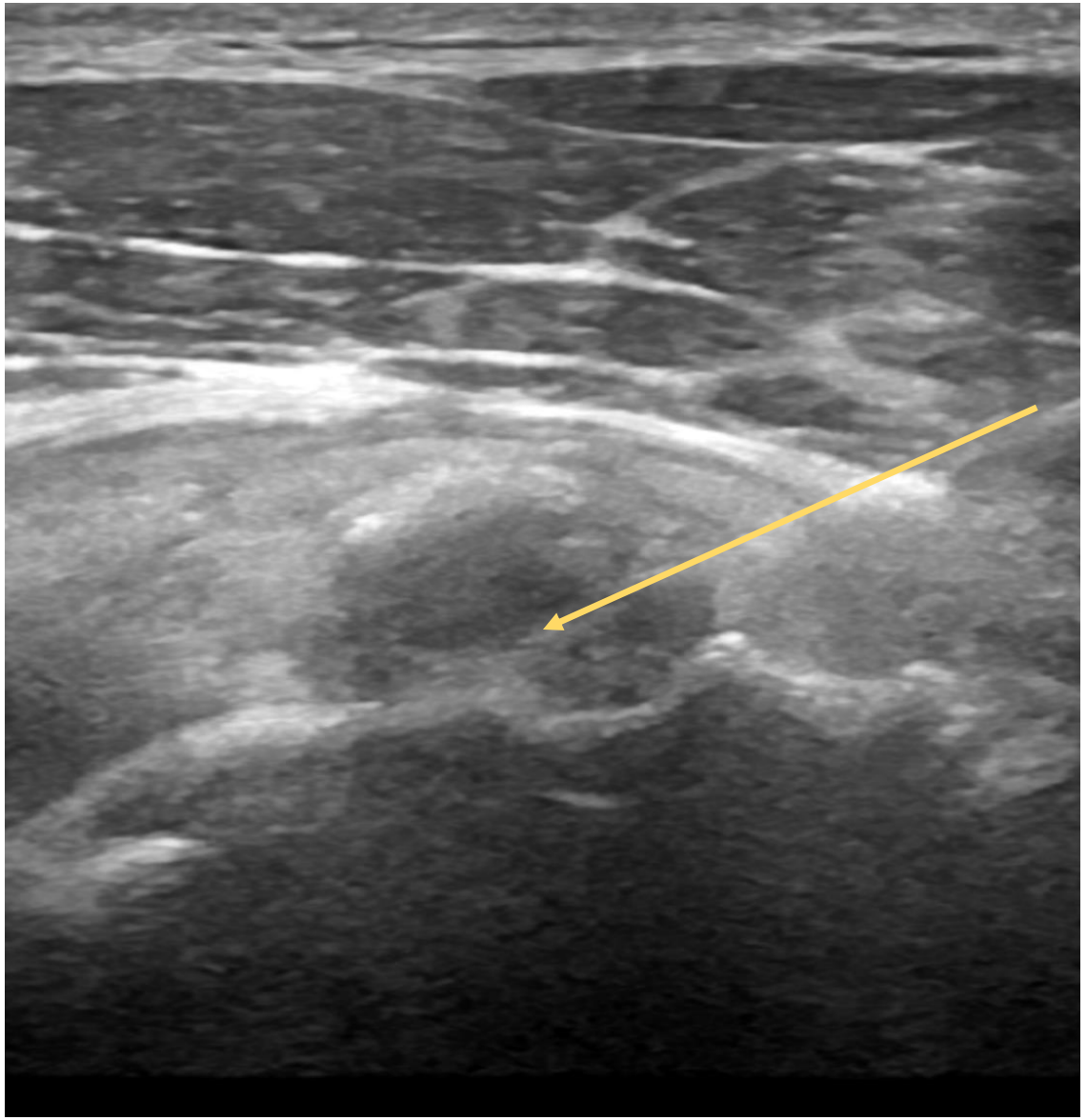

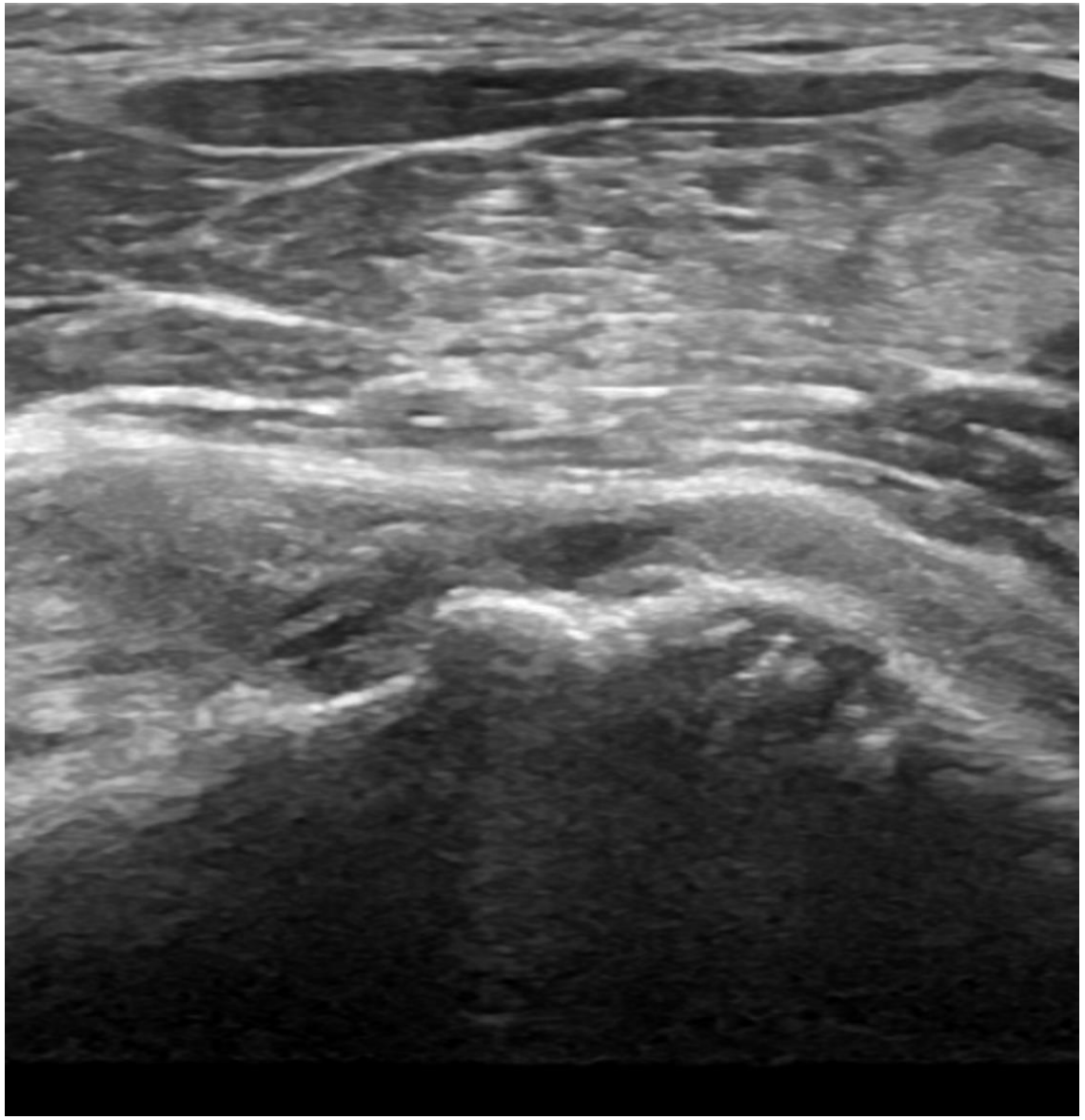



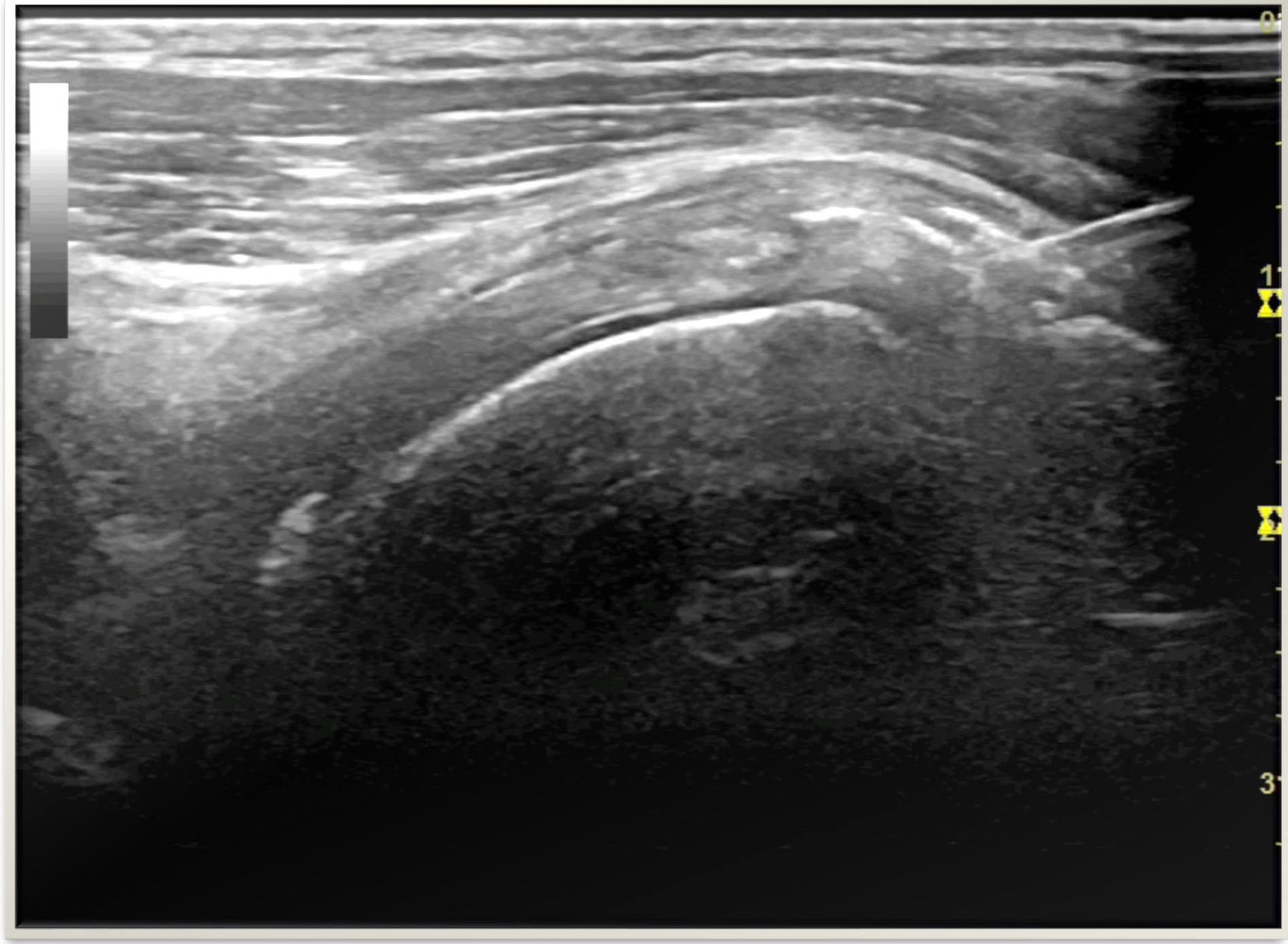

Stem Cell Treatment of Elbow

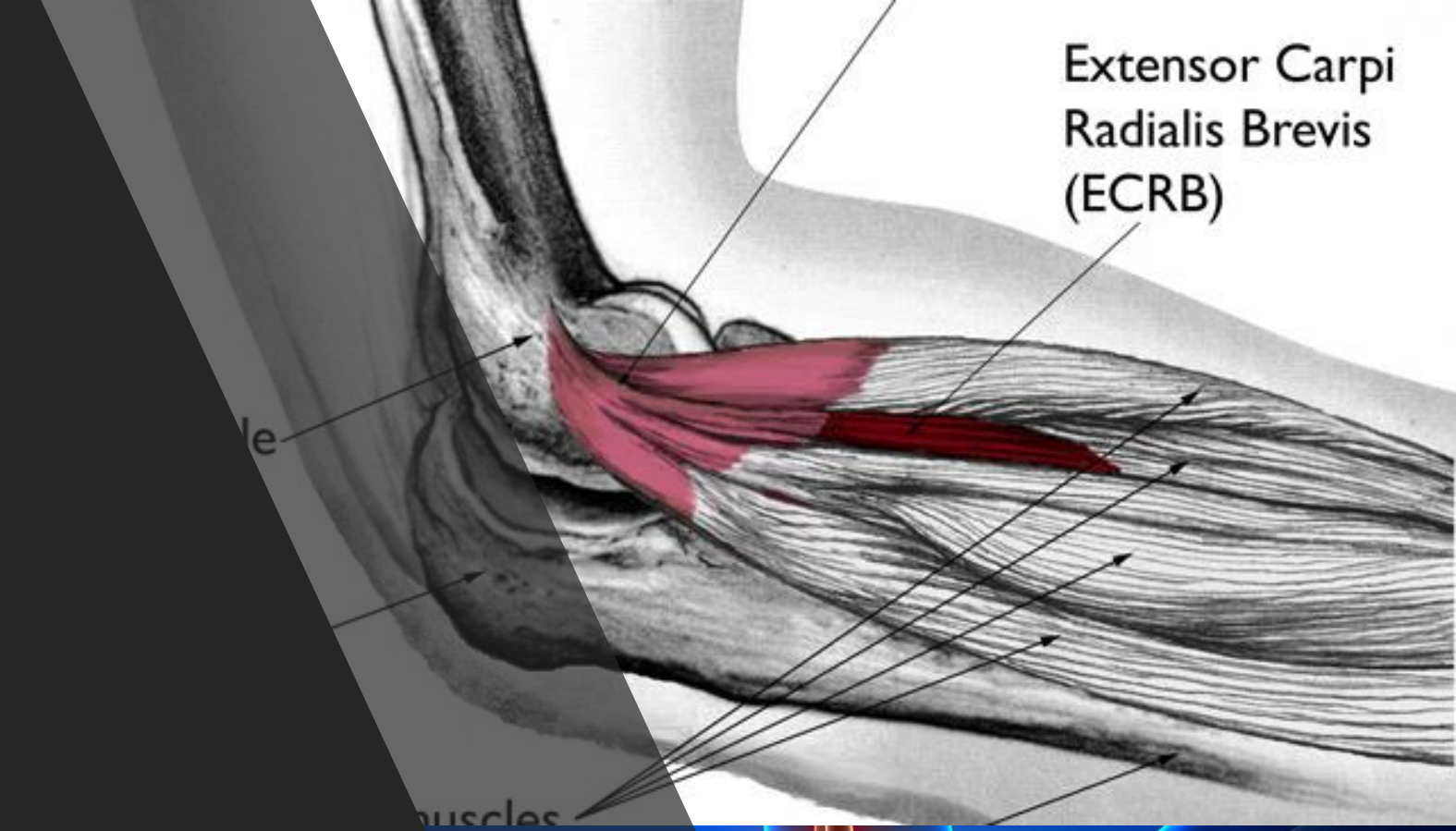



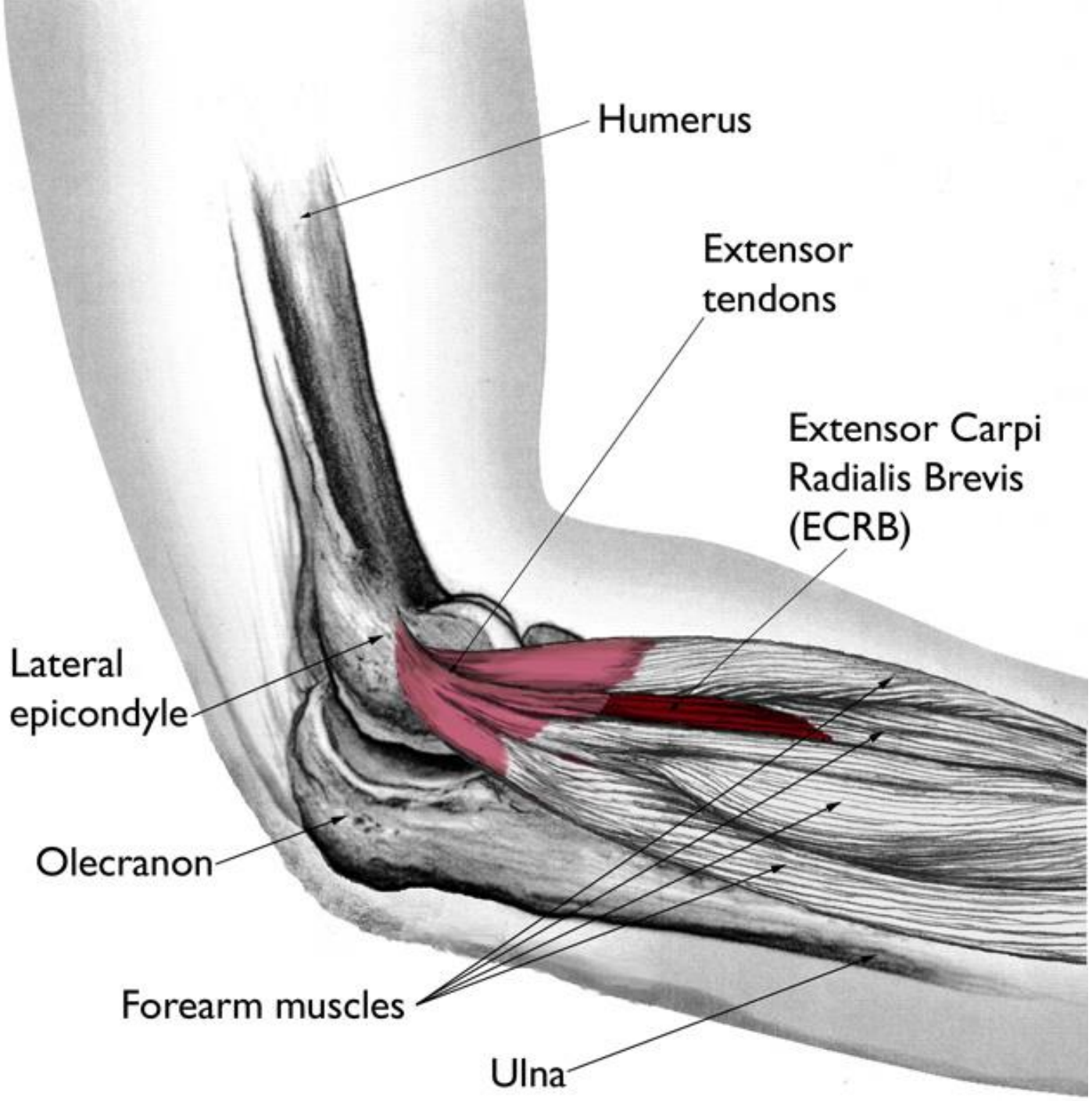
Humerus
Extensor tendons
Extensor Carpi Radialis Brevis (ECRB)
Lateral epicondyle
Olecranon
Forearm muscles
Ulna

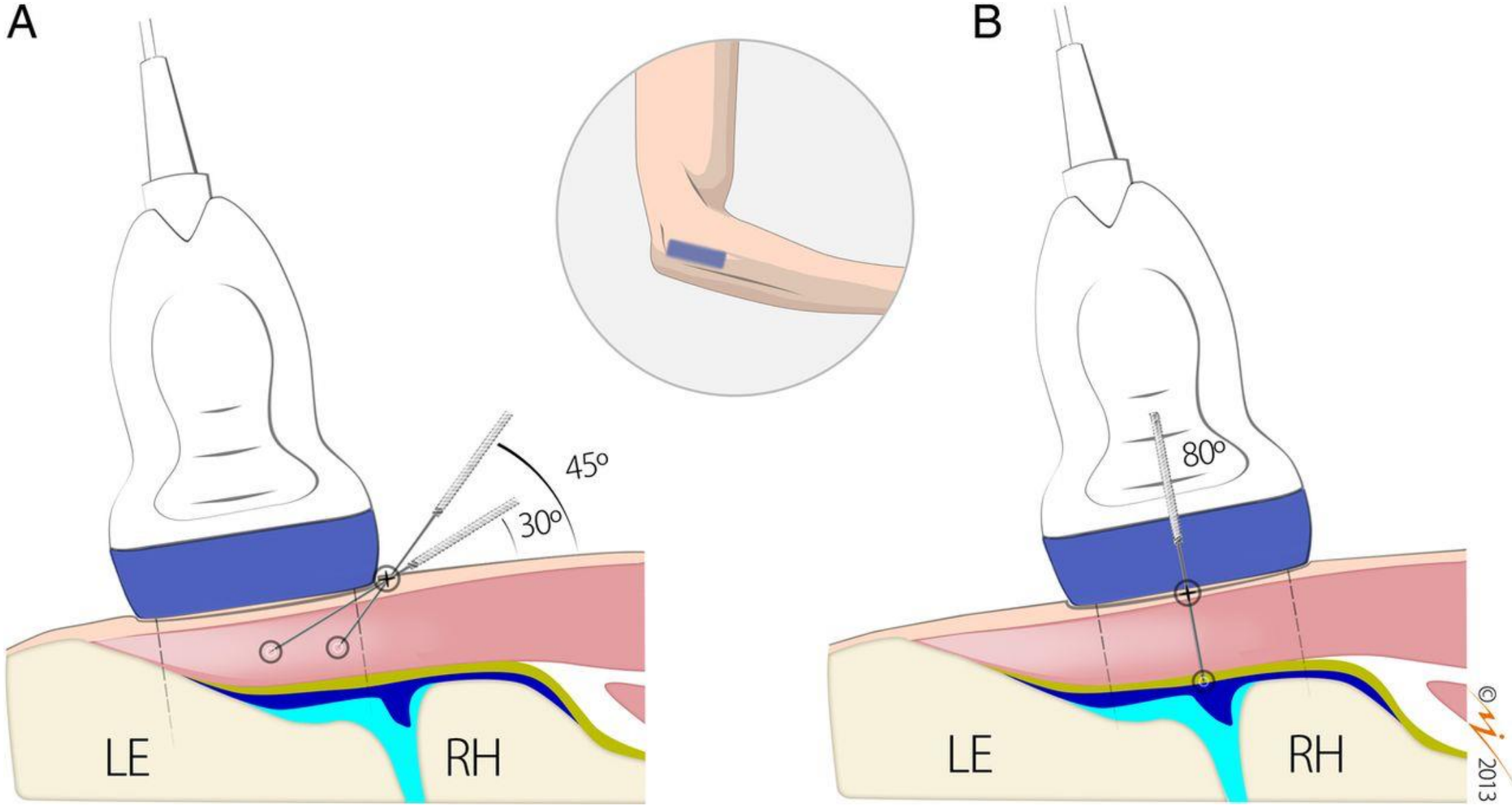
A
45°
30°
LE
RH
B
80°
LE
RH
©2013

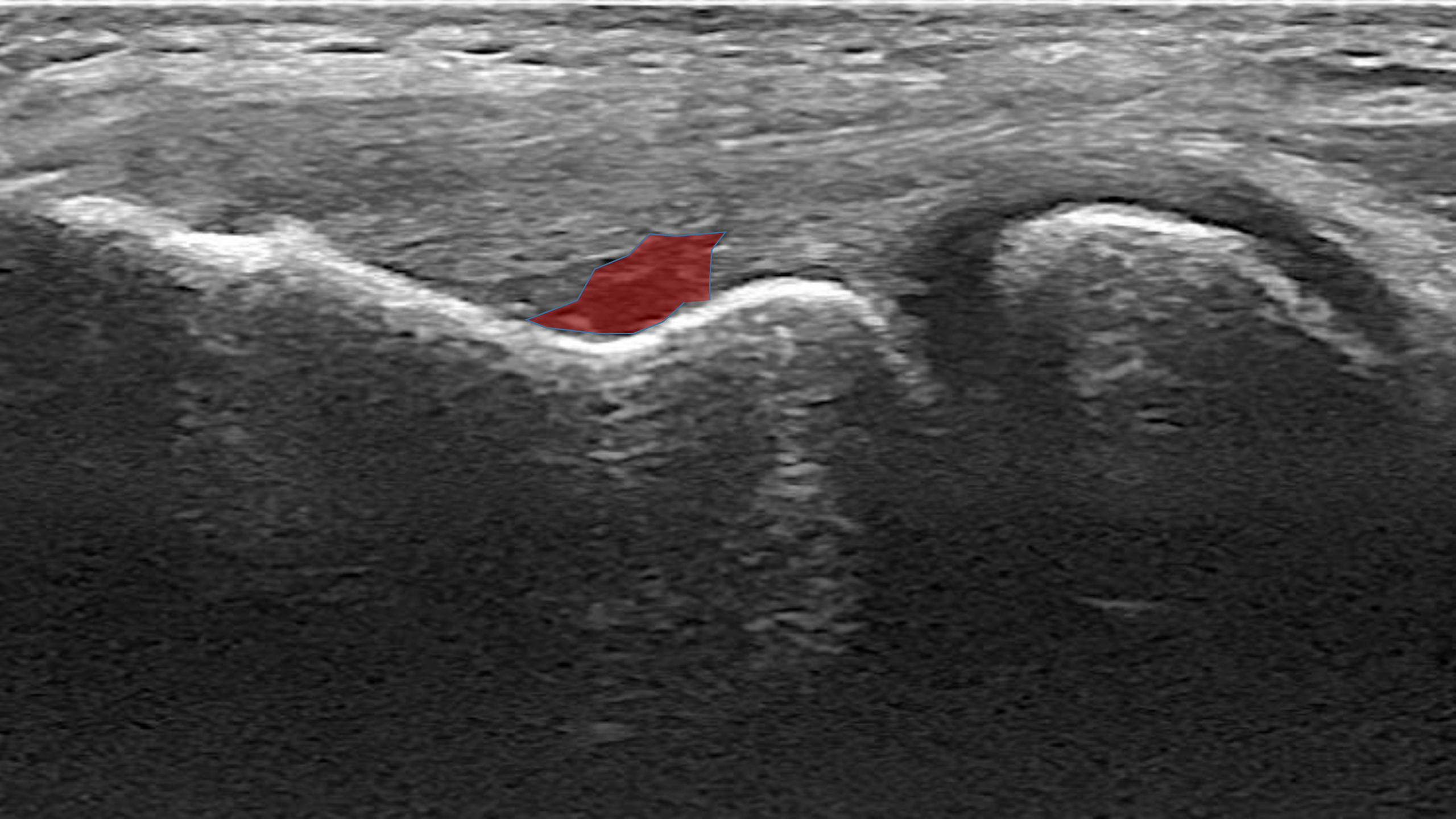





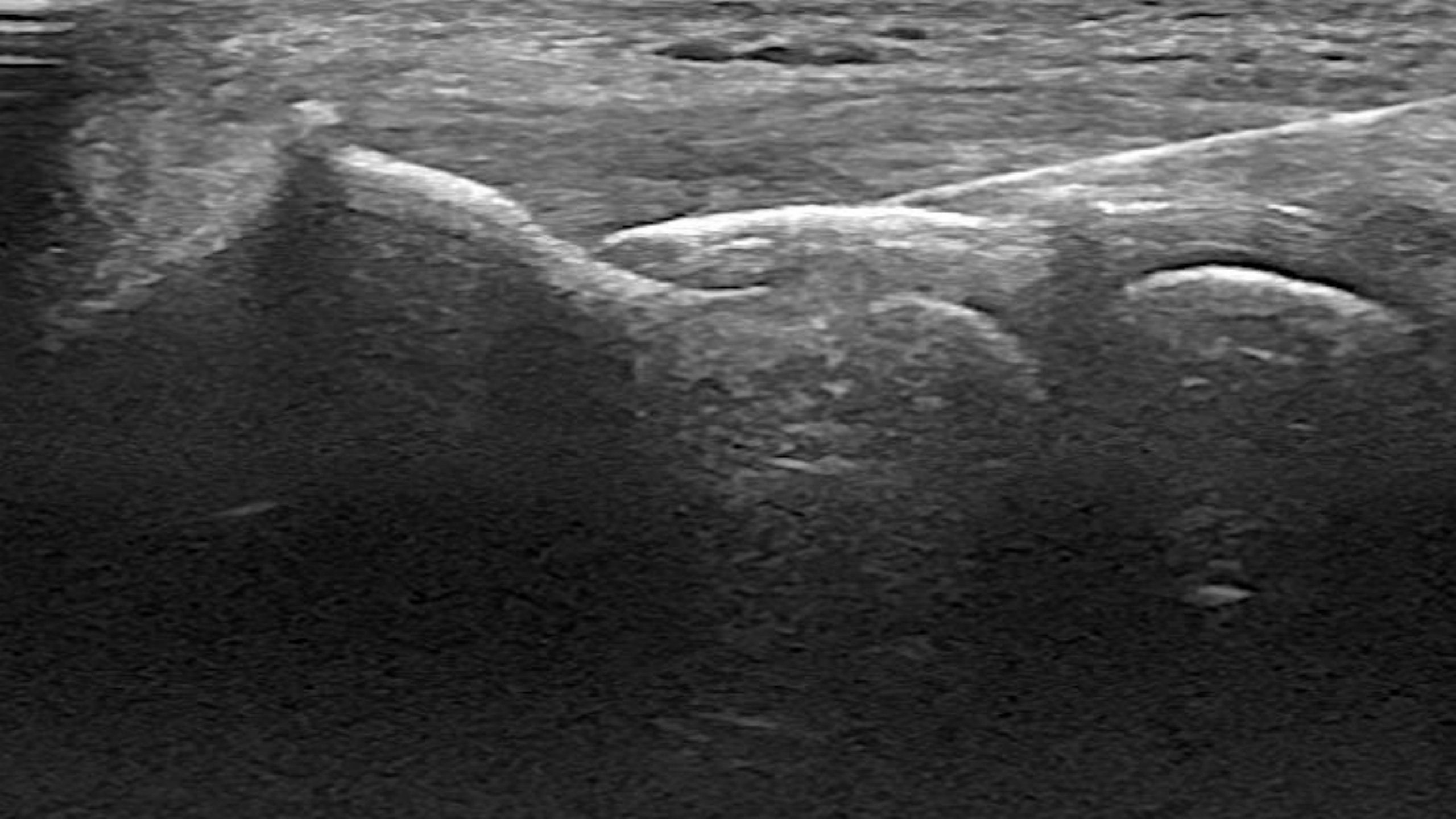

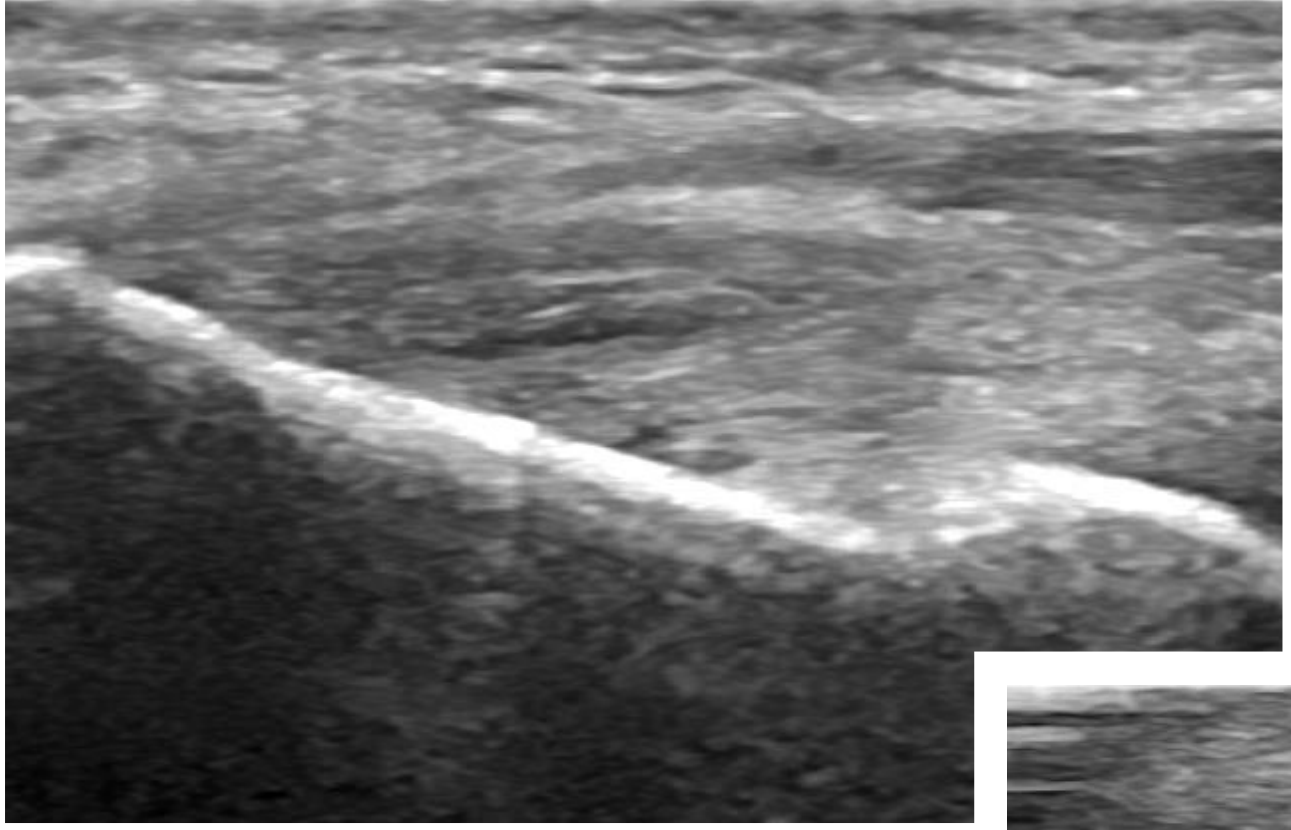



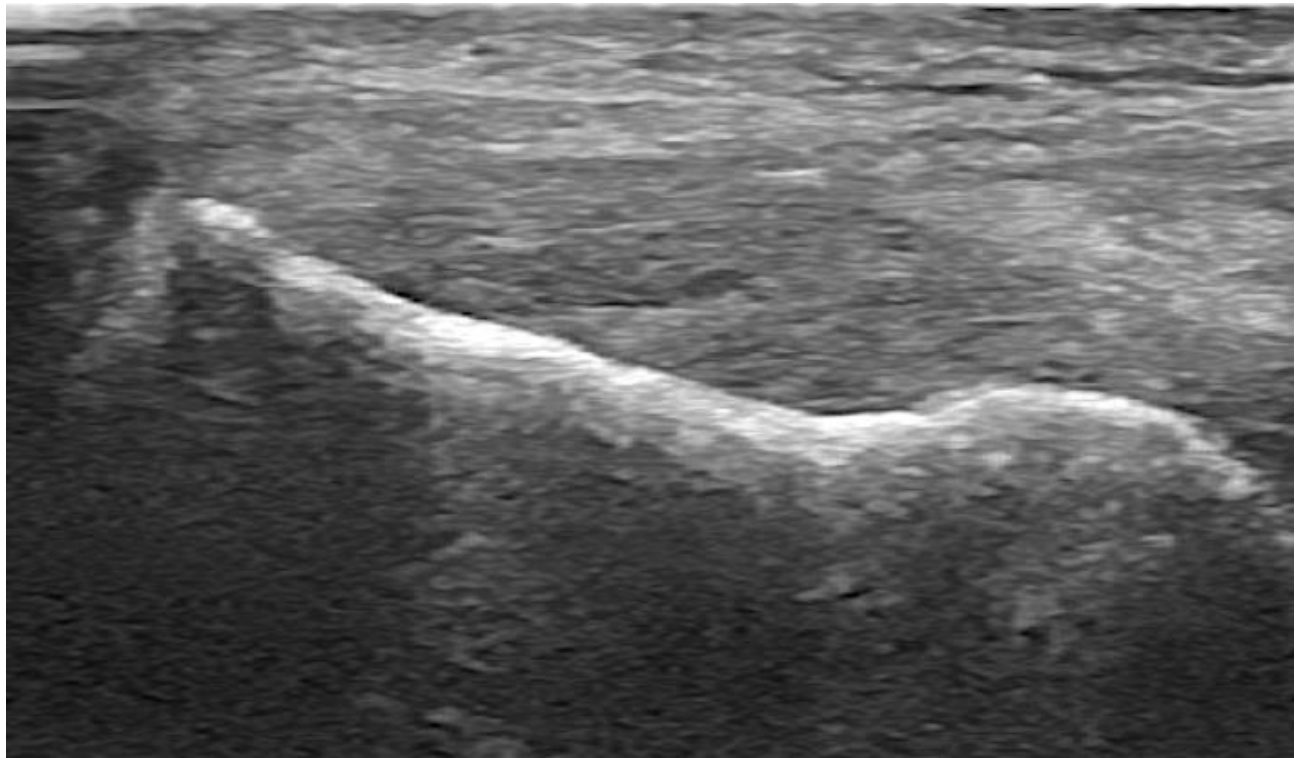









Achilles Tendon Treatment

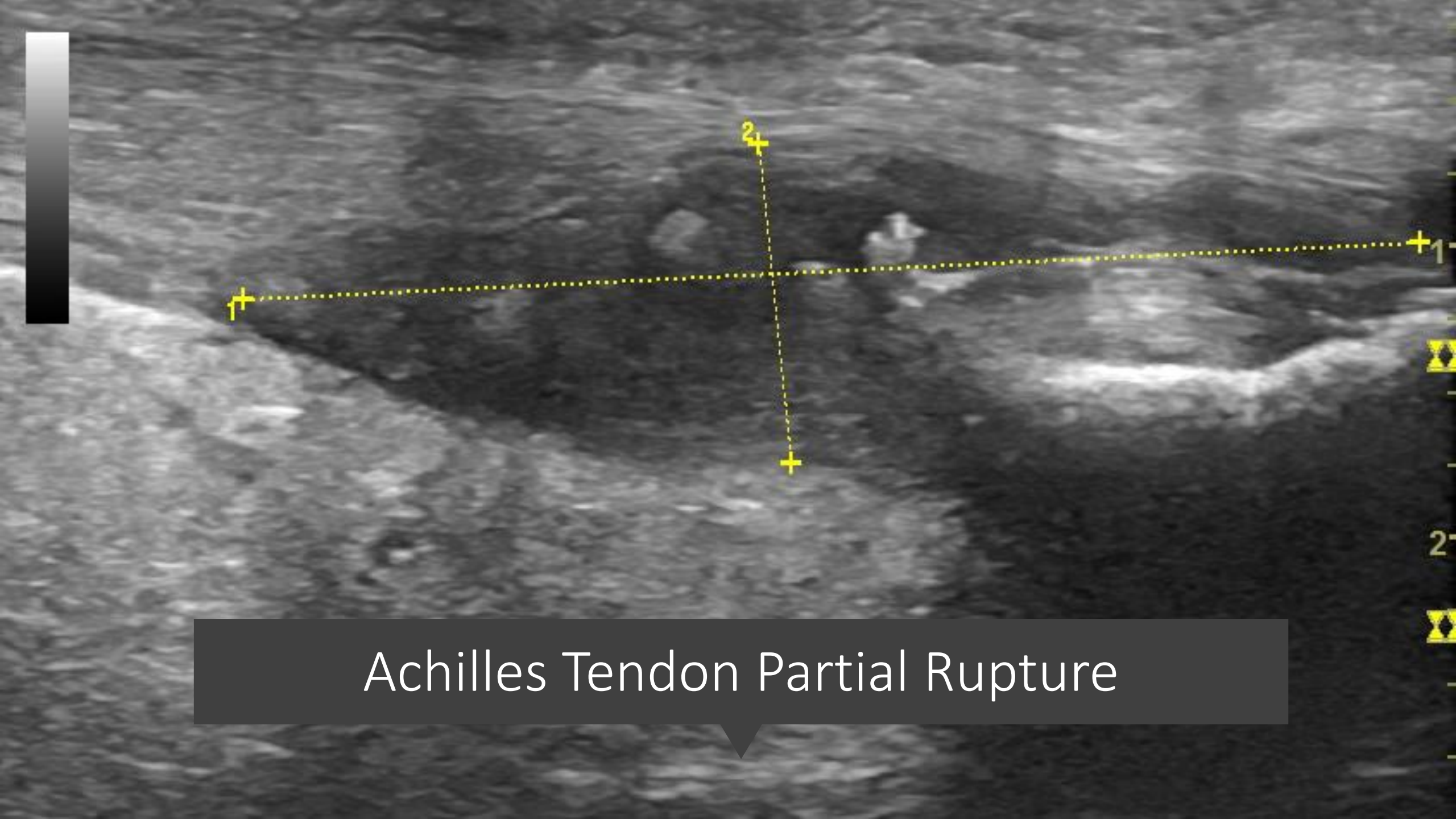
Achilles Tendon Partial Rupture



Sagittal Image

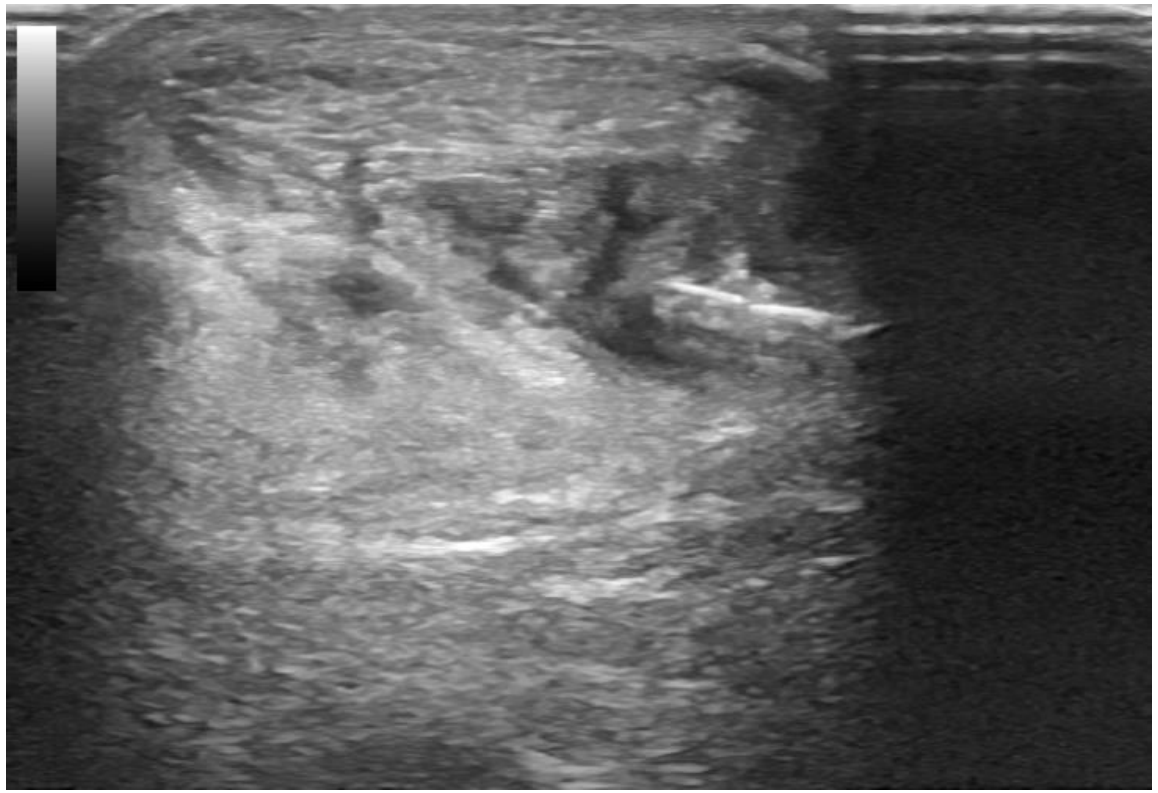

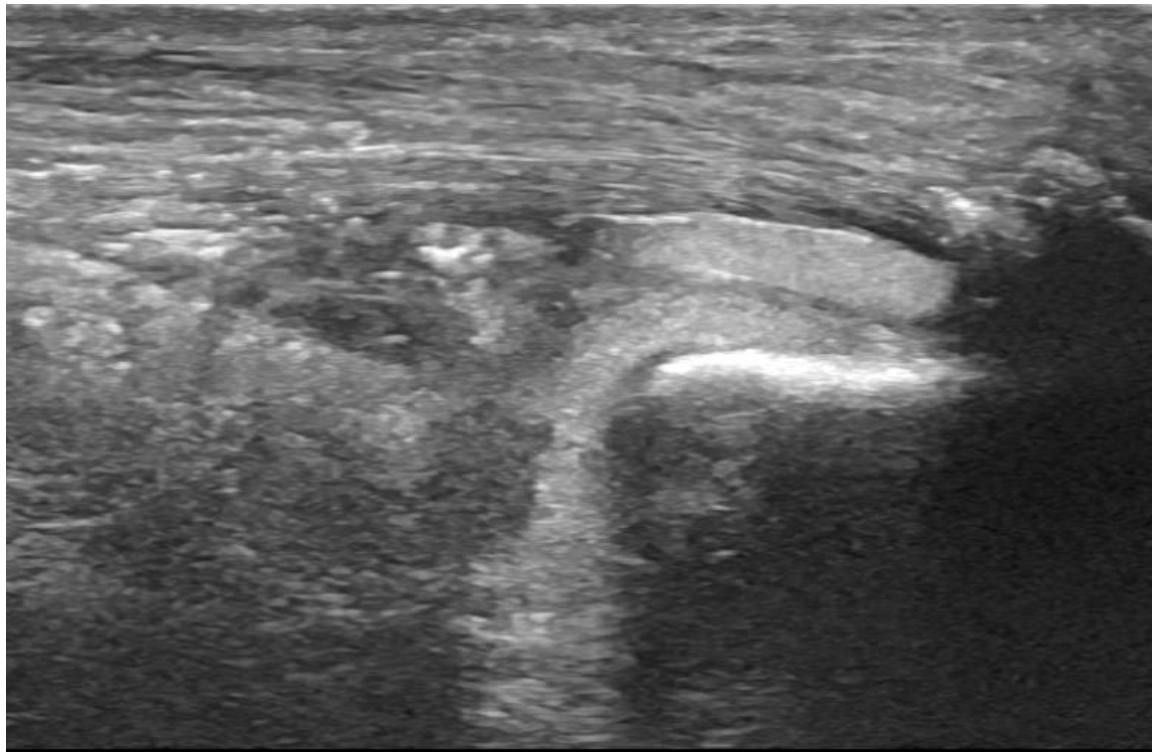

Stem Cell Injection

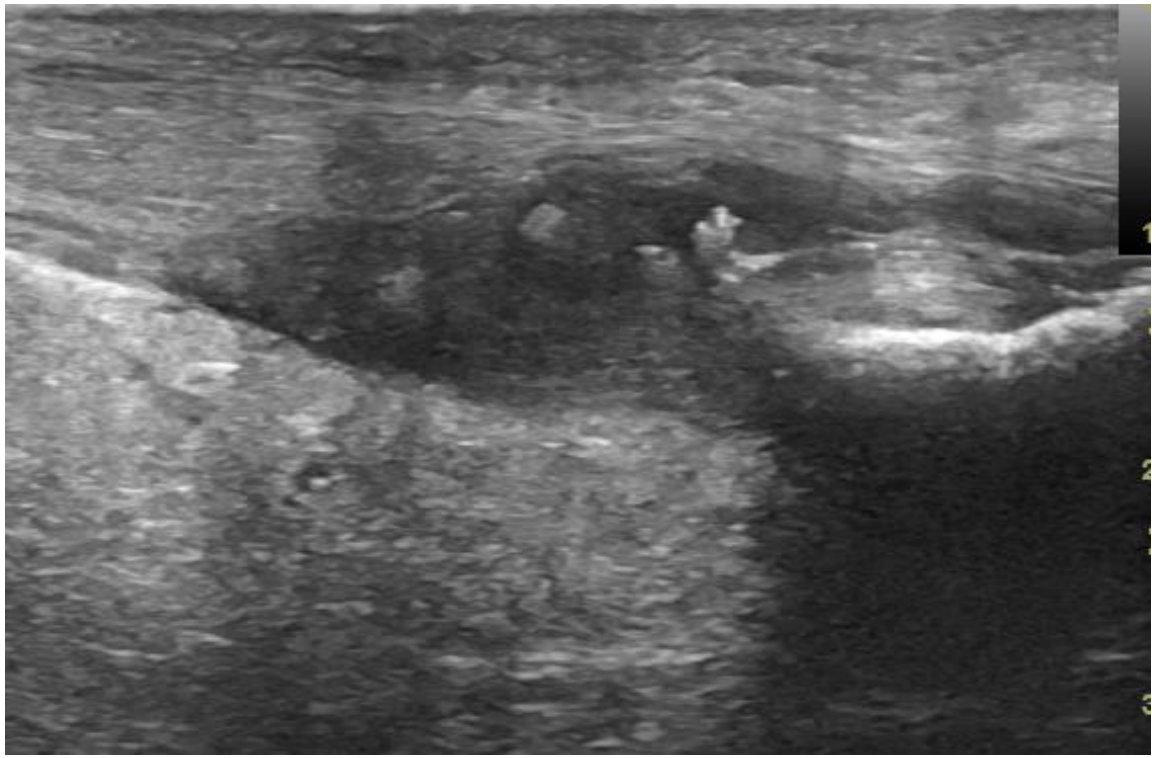

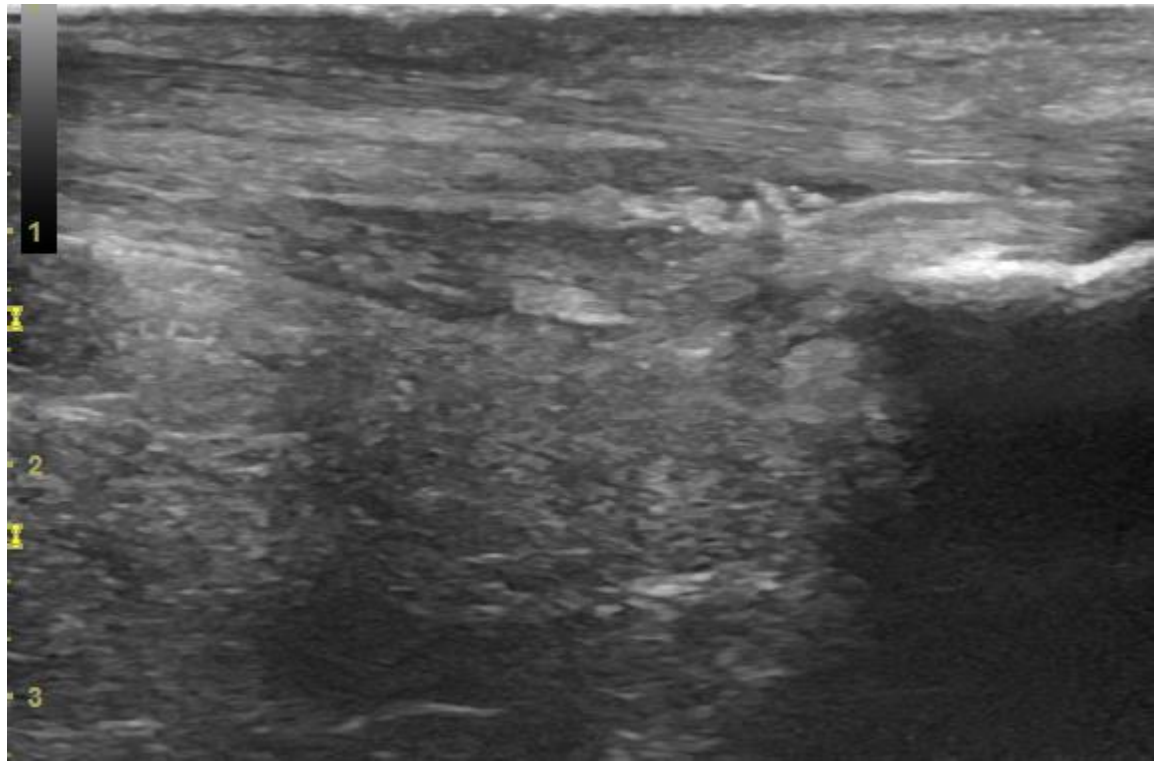

Pre and Post Images

Stem Cell Treatment of the Knee

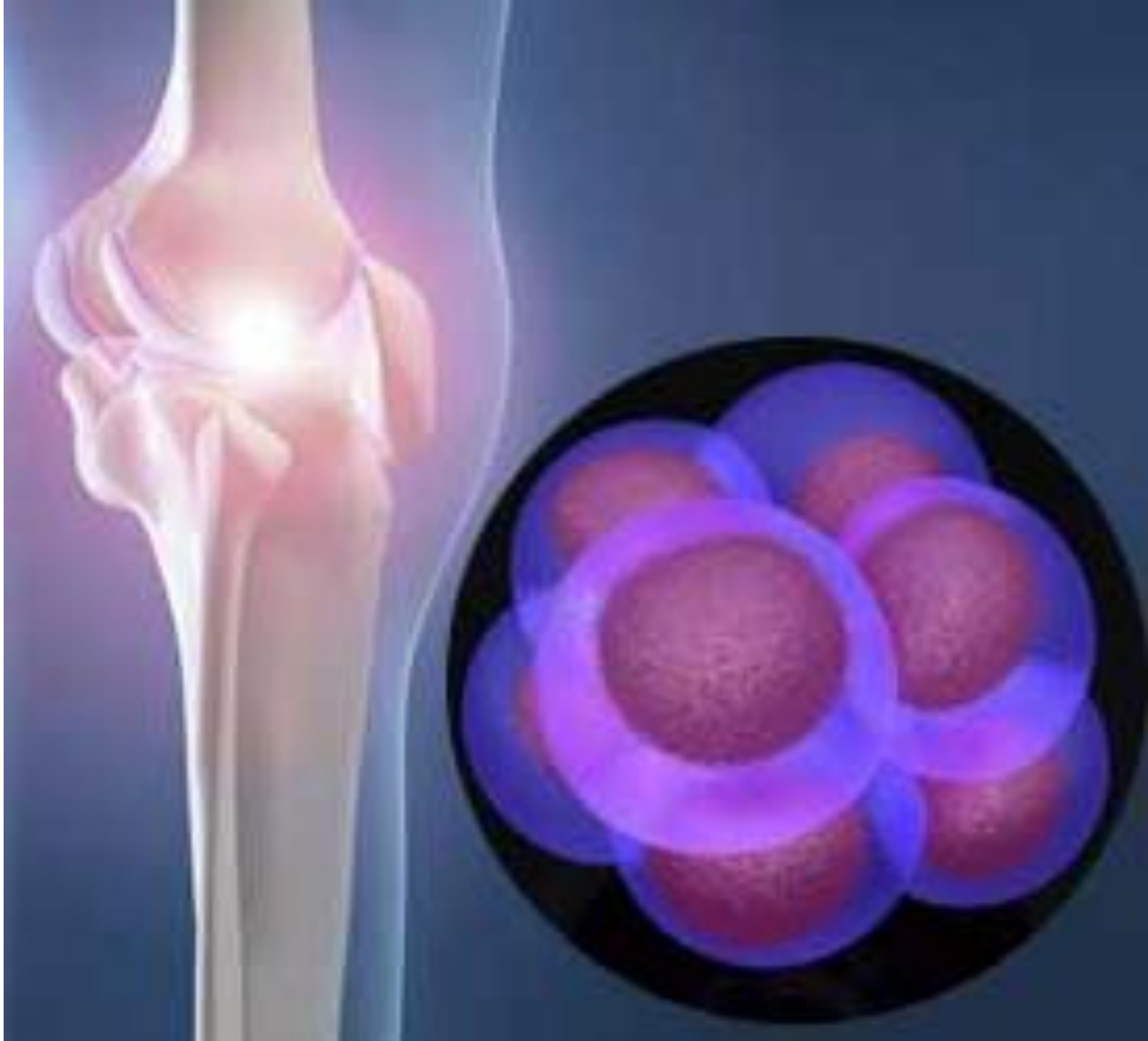

Studies

Intra-articular bone marrow concentrate injection protocol: short-term efficacy in osteoarthritis

Results: Median absolute pain reduction in all joints was five points (71.4%) on visual analog scale. Median patient satisfaction was 9.0/10, while 91.7% indicated that they would repeat the procedure and 94% said that they would recommend the procedure to a friend.

Steven Sampson, et al. Intra-articular bone marrow concentrate injection protocol: short-term efficacy in osteoarthritis. Regenerative Medicine 2016;11(6):511–20.

Studies

Prospective, Single-Blind, Placebo-Controlled Trial of Bone Marrow Aspirate Concentrate for Knee Osteoarthritis

Results: There were no serious adverse events from the BMAC procedure. OARSI Intermittent and Constant Osteoarthritis Pain and VAS pain scores in both knees decreased significantly from baseline at 1 week, 3 months, and 6 months (*P* .019 for all).

Significant improvement in the activity level compared with baseline for each of the 1-week, 3-month, and 6-month follow-up periods (P .024 for all). Self-reported pain medication usage decreased as well. Before the study, 100% of patients were using over- the-counter or prescription medications for pain, which decreased at the 3- and 6-month time points, to 24% and 36%, respectively.

Shapiro SA, Kazmerchak SE, Heckman MG, Zubair AC, O'Connor MI. A Prospective, Single-Blind, Placebo-Controlled Trial of Bone Marrow Aspirate Concentrate for Knee Osteoarthritis. Am J Sports Med. 2017 Jan;45(1):82–90.



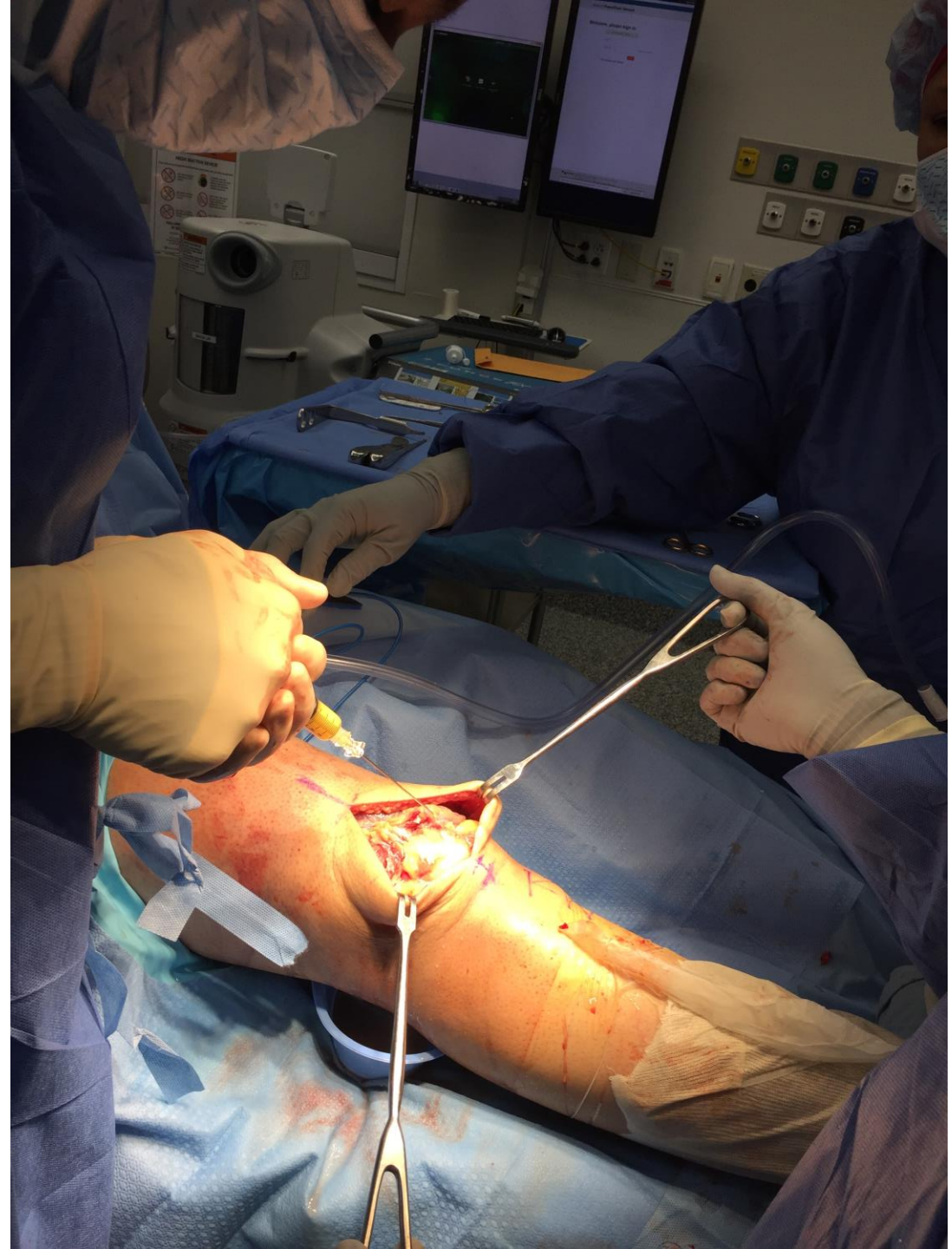

The Future is Bright

Thank You